


**CASE REPORT**

## The Endobronchial Inflammatory Myofibroblastic Tumor

Imane Lefqih , Labiba SbikiI, Hachem Taleb Elmine, Safa Sabur, Rachid Taoufiq, Abdellah Achir, Mohamed Bouchikh  
Service de Chirurgie Thoracique, CHU Ibn Sina, Rabat.

**ABSTRACT**

The inflammatory myofibroblastic tumor is a rare tumor described in the literature as a type of inflammatory pseudotumor. It mainly has a pulmonary location but can appear at endobronchial or mediastinal sites on rarely. While it is a benign tumor, it can sometimes be unpredictable due to its invasive characteristic as well as its resurgence after complete excision.

We report the case of a patient presenting hemoptysis. The bronchoscopy revealed a bud in the left upper lobe bronchus, and the biopsy pointed to a myofibroblastic tumor. In one month, interval, the bud extended to the left main bronchus, hence the indication of a left pneumonectomy, performed by posterolateral thoracotomy. The study of the operative specimen confirmed the biopsy diagnosis. The particularity of our case is the endobronchial presentation and the fast evolution of this inflammatory myofibroblastic tumor, which requires a pneumonectomy.

**KEYWORDS:** Inflammatory myofibroblastic tumor; Endobronchial; Surgery; Pneumonectomy.

**Correspondence:** Dr Imane Lefqih, Service de Chirurgie Thoracique, CHU Ibn Sina, Rabat.  
Email: [imane.lefqih@gmail.com](mailto:imane.lefqih@gmail.com)

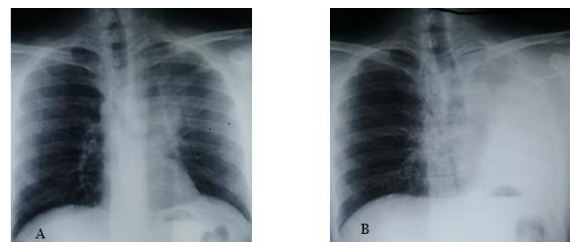
**Copyright © 2020 Lefqih I et al.** This is an open access article distributed under the [Creative Commons Attribution 4.0 International](https://creativecommons.org/licenses/by/4.0/), which permits unrestricted use, distribution, and reproduction in any medium, provided the original work is properly cited.

**INTRODUCTION**

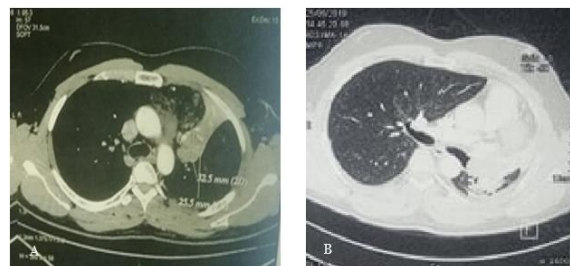
Inflammatory myofibroblastic tumors constitute only less than 1% of pulmonary tumors. It is a neoplasia and not a reaction lesion. Former appointments of those tumors have been abandoned such as inflammatory pseudotumors, plasma cell granuloma or histiocytomas [1]. The preoperative diagnosis is difficult to establish and the anatomopathological examination of the operative specimen is of major interest [2]. Through this observation, emphasis has been placed on the end bronchi allocation, and the fast and unpredictable evolution of such tumor.

**CASE REPORT**

F.B. is 30 years old patient with a history of stage I Hodgkin's lymphoma classified as a nodular sclerosing type. It was treated by chemo radiotherapy in 2018 and he was declared cured. A passive smoker, the patient has been suffering for 7 months of hemoptysis, dyspnea stage III of the New York Heart Association (NHYA) and episodes of repeated respiratory infections, without chest pain nor deterioration of his health. Chest radiography has uncovered a linear apical left opacity (Figure1-A). Furthermore, a chest CT has shown a tumor at the level of left upper lobe bronchus with atelectasis of the left upper lobe (Figure 2 -A).



**Figure 1:** -A: Chest-x-ray showing an obliquely oriented, on-homogenous linear opacity -B: chest-x-ray showing an unilateral white lung with remarkable tracheal deviation.

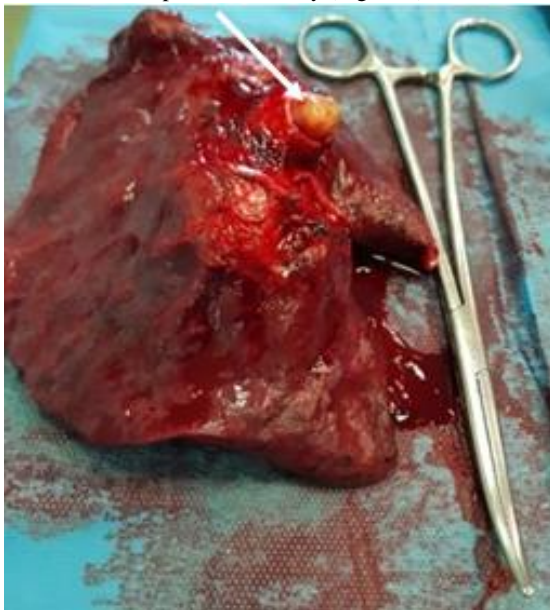


**Figure 2:** - A: Computed tomography revealed an endobronchial mass obstructing the left upper bronchus; -B: Left lung atelectasis

The bronchoscopy points to a bud obstructing the orifice of the left upper lobe bronchus. Biopsy examination has shown the proliferation of a fusocellular tumor in the bronchial mucosa. The result of the immunohistochemical study is compatible with inflammatory myofibroblastic tumor.

The evolution of the patient's state during clinical stay was marked by an acute respiratory distress reported as a hypoxemic viral pneumopathy. A month later, chest radiography showed an unilateral white lung (Figure1-B), a second bronchoscopy was performed, showing a bud completely obstructing the left main bronchus. A second computed tomography was performed preoperatively. It revealed the extension of the tumor to the left main bronchus, and the total atelectasis of the left lung (Figure2-B).

The preoperative assessment included a functional exploration with an FEV1 equal to 54%. The patient could not bear the maximal oxygen consumption testing whereas the result of the Stair-Climb test was satisfactory. The echo cardiography and the biological assessment showed no abnormality other than the reactive protein-c, which was at 7.93mg/l, hence the decision for left pneumonectomy (Figure 3).



**Figure 3:** Left pneumonectomy, a bud (white arrow) in the left main bronchus with extra-luminal component

Postoperative recoveries were simple, the histopathological study of the operative specimen showed an inflammatory myofibroblastic tumor with a proliferation index Ki67 estimated at 10%. The bronchial cut was intact. At the most recent follow-up (12 months after operation), the patient presented good clinical condition and there was no evidence of recurrence in the chest CT scan.

## DISCUSSION

Inflammatory myofibroblastic tumors are rare as they represent only less than 0.7% of lung tumors. They can occur in many anatomical sites with a locally aggressive or multifocal tendency [1,3].

Other extrathoracic localizations have been described either as synchronous or metachronous [3].

Myofibroblastic tumors are more common at age under 16 and the majority of cases reported are for age under 40 years old [1]. Although most of the cases described in the literature are male, male predilection is not confirmed [5]. These tumors have had several nominations: inflammatory pseudotumor, plasma cell

Granuloma and fibrous histiocytoma [3]. Currently, these tumors are classified as borderline tumors; they are composed of a proliferation of spindle cells like myofibroblasts and fibroblasts, with inflammatory infiltrate composed of plasma cells, lymphocytes and eosinophils [3,5].

Their etiopathogenesis is not yet explained, for some authors it is a tissue reaction caused by a local aggression, particularly in the context of trauma, surgery or infection. For other authors, it is a chromosomal abnormality at the 23<sup>rd</sup> pair of chromosomes inducing changes at the level of the ALK which favors a neoplasia origin [6]. Half of the inflammatory myofibroblastic tumors host rearrangements in the anaplastic lymphoma kinase (ALK) genes [5].

The clinical symptoms found are: cough, chest pain, dyspnea, hemoptysis and sometimes fever. Some cases can take asymptomatic forms. These tumors may come with an increase of the reactive c-protein [7]. The radiological aspects are variable: single or multiple parenchymal opacity, atelectasis in the bronchial localizations and cavitation. The calcifications are frequent in the child cases [8]. The tomography by positron emission shows fixation to FDG [1].

It is difficult to distinguish the myofibroblastic inflammatory tumors from the malignant tumors at the base of biopsy only, surgical resection makes it possible to establish the correct diagnosis [7]. In this case, the diagnosis was achieved through bronchoscopy. The differential diagnosis will depend on the radio-clinical presentation of the case. The differential diagnosis includes lung cancer, chondroma and pulmonary granuloma. Also, endobronchial lesions can simulate carcinoid tumors [3].

There are few published series in the literature about endobronchial inflammatory

Myofibroblastic tumor, the last was in 2011 about 11 patients [9]. Surgery is the most effective treatment; this section must be complete in order to avoid tumor recurrences [1]. Surgical excision is the only therapeutic attitude due to ineffectiveness of medical treatment based on corticosteroids, immunosuppressives agents, radiotherapy and chemotherapy [10].

However, certain chemotherapeutic agents such as paclitaxel and carboplatin may have their place in the context of an unresectable tumor or after local resurgence. ALK inhibitor has been used in cases where ALK results have been positive [11].

Chemotherapy (vincristine, methotrexate) and radiation are reserved for patients who had incomplete resection, metastatic locations and also for those who had a high intraoperative mortality [12, 9].

Surgical resection is the main treatment for inflammatory myofibroblastic tumors. In this case the fast growth and the extension of the bud in the left main bronchus requires a pneumonectomy. A favorable prognosis depends on the seizure and the complete surgical resection

of the tumor. The 3-year survival rate is 82% and the 5-years survival rate is around 74%[13].

## CONCLUSION

Inflammatory myofibroblastic tumors constitute only less than 1% of pulmonary tumors; their endobronchial location is very rare. Preoperative diagnosis is difficult and early surgery remains the best treatment for this benign but extensive entity

## ACKNOWLEDGMENTS

None.

**AUTHORS' CONTRIBUTIONS** The participation of each author corresponds to the criteria of authorship and contributorship emphasized in the [Recommendations for](#)

## REFERENCES

- [1] SHantous Zannad, SEsseghaier, IRid'ene, AZidi, IBaccouche, A Ayadi-Kaddour, TKi-lani, and K Ben Miled-M'rad. Imagerie des tumeurs myofibroblastiques inflammatoires du poumon. *Journal de Radiologie*, 90(12):1851–1855,2009.
- [2] Marine Peretti, Dana M Radu, Karel Pfeuty, Antoine Dujon, Marc Riquet, and Emmanuel Martinod. Surgical resection of pulmonary inflammatory pseudotumors: long-term out-come. *Asian Cardiovascular and Thoracic Annals*, 25(6):440–445, 2017
- [3] Robert J Cerfolio, Mark S Allen, Antonio G Nascimento, Claude Deschamps, Victor F Trastek, Daniel L Miller, and Peter C Pairolero. Inflammatory pseudotumors of the lung. *The Annals of thoracic surgery*, 67(4):933–936, 1999.
- [4] Herbert C Maier and Sheldon C Sommers. Recurrent and metastatic pulmonary fibrous histiocytoma/plasma cell granuloma in a child. *Cancer*, 60(5):1073–1076, 1987.
- [5] Jason C Chang, Lei Zhang, Alexander E Drilon, Ping Chi, Rita Alaggio, Laetitia Borsu, Ryma Benayed, William D Travis, Marc Ladanyi, and Cristina R Antonescu. Expanding the molecular characterization of thoracic inflammatory myofibroblastic tumors beyond alk gene rearrangements. *Journal of Thoracic Oncology*, 14(5):825–834, 2019.
- [6] Nicolas SIRVENT, Jean-Miche COINDRE, and Florence PEDEUTOUR. Tumeurs myofibroblastiques inflammatoires. In *Annales de pathologie (Paris)*, volume 22, pages 453–460, 2002.
- [7] Adil Arsalane, Hicham Fenane, Amine Azami, Simohamed Mzouri, and Abdelfetah Zidane. A rare tumor

[the Conduct, Reporting, Editing, and Publication of Scholarly work in Medical Journals of the International Committee of Medical Journal Editors](#). Indeed, all the authors have actively participated in the redaction, the revision of the manuscript, and provided approval for this final revised version.

## COMPETING INTERESTS

The authors declare no competing interests with this case.

## FUNDING SOURCES

None.

## PATIENTS' CONSENT

Written informed consent was obtained from the patient for the publication of this case report.

- of the mediastinum: Inflammatory myofibroblastic tumor. *International Journal of Medicine and Surgery*, 6(r), 2019.
- [8] Dominique Fabre, Elie Fadel, Sunil Singhal, Vincent de Montpreville, Sacha Mussot, Olaf Mercier, Olivier Chataigner, and Philippe G Dartevelle. Complete resection of pulmonary inflammatory pseudo tumors has excellent long-term prognosis. *The Journal of thoracic and cardiovascular surgery*, 137(2):435–440, 2009.
  - [9] Patricia A Thistlethwaite, John Renner, David Duhamel, Samir Makani, Grace Y Lin, Stuart W Jamieson, and James Harrell. Surgical management of endobronchial inflammatory myofibroblastic tumors. *The Annals of thoracic surgery*, 91(2):367–372, 2011.
  - [10] F Girard, M Kambouchner, S Maugendre, JM Naccache, and R De Meyer-Cristiani. Pseudo-tumeurs inflammatoires pulmonaires d'évolution sévère. *Revue des maladies respiratoires*, 18(5):541–544, 2001.
  - [11] Nikolaos Panagiotopoulos, Davide Patrini, Lasha Gvinianidze, Wen Ling Woo, Elaine Borg, and David Lawrence. Inflammatory myofibroblastic tumour of the lung: areactive lesion or a true neoplasm? *Journal of thoracic disease*, 7(5):908, 2015.
  - [12] Vishnukanth Govindaraj, Debasis Gochhait, Balla Nagamalli Kumar, and Suryakala Narayanasami. Endobronchial inflammatory myofibroblastic tumour- a case report. *Journal of clinical and diagnostic research: JCDR*, 10(8):OD07, 2016.
  - [13] Chien-Kuang Chen, Chia-Ing Jan, Jian-Shun Tsai, Hsu-Chih Huang, Pin-Ru Chen, Yu-Sen Lin, Chih-Yi Chen, and Hsin-Yuan Fang. Inflammatory myofibroblastic tumor of the lung- a case report. *Journal of Cardiothoracic Surgery*, 5(1):1–4, 2010.