

REVIEW

How to Overcome Bone Resorption in Complete Removable Prosthesis?

Anissa Regragui ¹  ; Najib Alidrissi ²  ; Amal Sefrioui ¹ , Faiza Benfdil ¹ , Nadia Merzouk ¹

¹ Removable prosthesis department, Mohammed V University in Rabat, Morocco

² Faculty of Medicine, Mohammed VI University of Health Sciences, Casablanca, Morocco.

ABSTRACT

The existence of alveolar processes and the integrity of the maxillae outside of a specific pathological process are linked to the presence of teeth. The aging process is most often accompanied, at the buccal level, by a narrowing of the prosthetic corridor in relation to the importance of bone resorption and the invasion of peripheral elements. Thus, we are and will be confronted more and more with complete edentulous patients, presenting a very strong resorption of the alveolar processes, even of the osseous bases, which will increase proportionally the difficulties of obtaining a good retention and good stability of the prostheses.

Our work aims to review the various means available to us to prevent bone resorption, throughout the stages of prosthetic and post-prosthetic realization.

KEYWORDS: Bone resorption-prevention-treatment-complete toothlessness- removable prosthesis.

Correspondence : Pr Anissa Regragui, Removable prosthesis department, Mohammed V University in Rabat, Morocco

E-mail : anissaregragui@yahoo.fr

Copyright © 2020 Anissa Regragui et al.

This is an open access article distributed under the [Creative Commons Attribution 4.0 International](https://creativecommons.org/licenses/by/4.0/), which permits unrestricted use, distribution, and reproduction in any medium, provided the original work is properly cited.

INTRODUCTION

Bone resorption of the ridges is common but the importance varies between individuals and also within the same subject depending on their age. The anatomical, metabolic, functional and prosthetic factors will all play an important role in the evolution of the ridge, but it must above all be understood that all of these factors are interdependent. Each of these factors must be assessed in relation to the others in order to assess bone resorption. (1) (2)

In fact, throughout life, bone is the seat of permanent changes. This process, which preserves the biomechanical properties of bone tissue, takes place according to a very precise chronology. It begins with a transition phase leading to the recruitment of osteoprogenitor cells, a new matrix is formed then becomes mineralized; this process involves close coupling between the absorption phase and the training phase. A remodeling sequence lasts on average between four to six months.

Although bone turnover is greatest in the first month after an avulsion, bone loss continues throughout life. (3) (4)

According to the work of Schropp and al. in 2003 (5), this post-extraction resorption can reach 50% of the total bone volume after one year. 2/3 of these changes occur during the first three months after the tooth is removed from the tooth. Resorption continues at a slower rate until reaching a percentage of 80% after two and a half years when it stabilizes without any aggravating factor. Osteoclastic activity leads, according to Araujo and Lindhe in 2005, to a reduction in the height and thickness of the crest much more pronounced in the vestibular than in the lingual. (6)

According to the meta analysis of Van der Weijden and al. In 2009, in humans, during the post-extractive healing period, the clinical loss in width of the alveolar ridge is greater than the loss in height. (7)

We will expose, in this work, the techniques and therapeutics in favor of a preservation of the bone capital by adopting an “oste-conscious” approach before and

throughout the stages of the prosthetic realization in the complete toothless.

**MEANS OF LIMITING BONE RESORPTION
PRE-PROSTHETIC MEANS**

+ Preventive treatment

Surgery and properly conducted extractions: The alveolar process is constituted at the same time as the development and the dental eruption. It gradually resolves after avulsion. Good management of avulsions makes it possible to limit the phenomenon of bone resorption by preserving the alveolar bone, by performing alveolectomies by the “benefit / risk” evaluation, by regulating the ridges with caution when necessary and by preserving the roots very buried (Fig. 1). (8) (9)

The surgical procedure is part of a global treatment program within which it is articulated with other therapeutic means. Compliance with a few principles optimizes the delivery of dental drive and its prognosis.

The study by Fickl and al. in 2008 demonstrates a negative effect of surgical extractions on the residual bone volume. It is best to do the ragless extraction, if possible. (10)

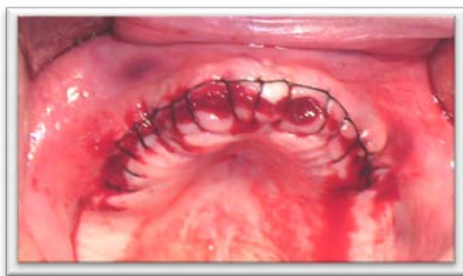

Fig. 1: Properly conducted dental extractions

Implants: In the context of rehabilitation by removable supra-implant complete prosthesis, these processes are intended to preserve the available alveolar height by maintaining the mechanical stimulation of bone tissue allowing permanent remodeling. (Fig.2a-b)

Atieh and al. reported a gain of 1.96 mm in bone around implants placed immediately after extraction compared to implants placed in healed ridges. (11) (12)

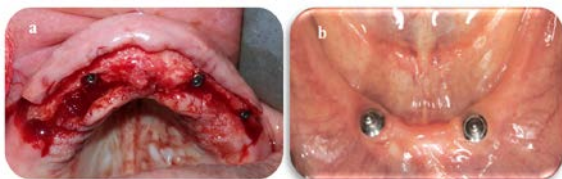


Fig. 2 a: Implant surgery ; **b:** 2 symphyseal implants

Overdentures: Preserving residual roots, when their intrinsic and extrinsic values are good, has the advantage of preserving bone capital as well as desodontal proprioception. The stability and retention of the prosthesis are improved. The reduction in the height of the residual teeth seems to decrease the overhang and the lateral forces, thus stimulating osteogenesis by transmission of the axial forces (Fig. 3a, b). (13) (14)

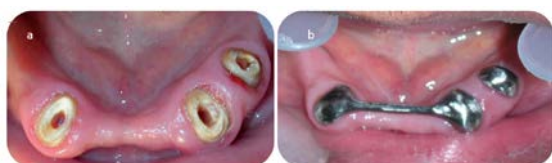

Fig. 3 a: Dental preparations in the event of overdentures **b:** Conjunction bar and parabolic support scree

Tissue conditioning (15) (16): Prostheses made from imprints of deformed or displaced tissues, according to Lejoyeux, accentuate any deformation and accelerate resorption.

Tissue conditioning is therefore indicated in the case of peri-prosthetic organs which have reduced the potential space reserved for the prosthesis or in the event of fibromucosal lesions which would minimize bone resorption. (Fig. 4 a, b and c)

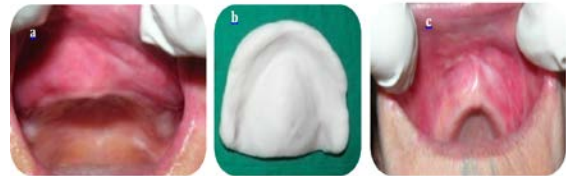


Fig. 4 a, b and c: Tissue conditioning and increase in biofunctional space

+ Curative treatment (17) (18) (19) (20) (8)

Subtractive surgery

• **Mucosal surgery:** A floating ridge no longer transmits stimulating forces for osteogenesis, so it is necessary to perform a suitable surgical resection to correct this risk factor accentuating bone resorption. (Fig. 5)

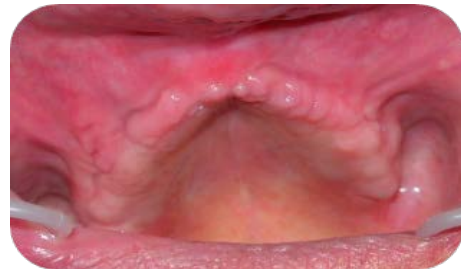

Fig. 5: Floating crest

• **Bone surgery:** Hypersensitive exostoses must be eliminated because they interfere with the adhesion of prosthetic bases and compromise osteogenic stimulation. (Fig. 6a-b)

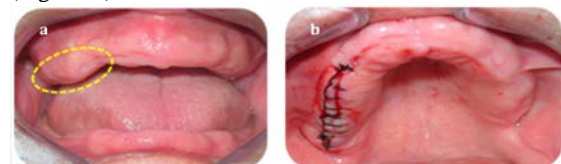

Fig. 6 a and b: bone enlargement requiring partial surgery

Additive surgery: The procedures for bone grafting and increasing the crestal volume are multiple and include apposition grafts, enlargement of the alveolar ridges, bone distraction, sandwich grafts, osteotomies (Fig. 7). In their systematic review, Milinkovic and Cordaro (2014) and Geivelis and al. (2019) confirmed that at the time of implant placement, dehiscence and fenestration can be successfully treated with guided bone regeneration. (19) (20)

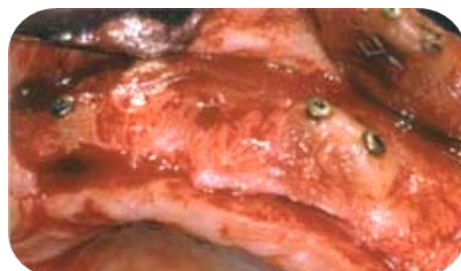


Fig. 7: Additive surgery (8)

PROSTHETIC MEANS

+ Immediate prosthesis

It slows down the post-extraction bone resorption process and stimulates osteoformation by maintaining the stress on the underlying bone via the functional forces transmitted through the fibromucosa (Fig. 8a, b and c). According to Wictorin, this prosthesis avoids the pathological resorption phase following dental extractions and decreases bone loss by 20 to 30% during the first year after implant placement. (21) (22)

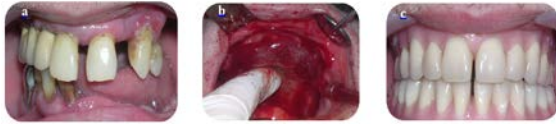

Fig. 8 a, b and c: Dental extraction guided by a surgical guide and immediate prosthesis for use in place

+ Impressions

Impressions play a vital role in tissue and prosthetic stability by recording details of the support surface as closely as possible without interfering with the peri-prosthetic organs. (Fig. 9)

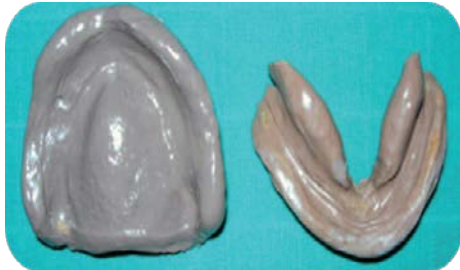

Fig. 9: Secondary impressions

+ Occlusion

The maxillo-mandibular ratios, the vertical dimension of occlusion, the sufficient space for free in occlusion, the centered relationship, will be carefully determined. (Fig.10)



Fig. 10: Maxillo-mandibular relationship

An occlusion plane that is too high or too low located, or too inclined will generate a loss of function at the molar level and an anterior overload, a source of accelerated resorption of the alveolar bone.

If the DVO is undervalued, a mandibular progression settles in search of previous dental contacts. This leads to an overload of the anterior fibromucosa and a loss of function in the posterior region, thereby causing bone resorption in both regions. An overestimated DVO may encroach on the clearance space, the continuous pressures would cause bone resorption.

A wrong centered relationship would lead to hyperfunction at the working side and hypofunction at the non-working side which would increase bone resorption. (23) (24)

+ Teeth (25) (23)

• Material : Resin teeth have the disadvantage of having a low resistance to long-term wear, causing a gradual loss of the vertical dimension of occlusion and of the occlusal

relations, mandibular progression and localized overloads, and consequently resorption. inevitable. The solution to be adopted is either the use of porcelain teeth or resin teeth with metal occlusal surfaces.

• Occlusal morphology : Cusp angulations of the order of 20 ° to 33 ° (Gysi or Artiplus teeth) ensure prosthetic stability and transmit the stresses favorable to stimulation of the underlying bone. In the event of strong resorption, teeth with less marked morphology are indicated.

• Dimensions : The dimensions of the prosthetic teeth should rather be reduced in the vestibulo-lingual direction to avoid harmful lateral forces which are sources of bone resorption.

• Mounting : A fully balanced occlusion seems to guarantee stability of the prosthesis. (Fig.11)

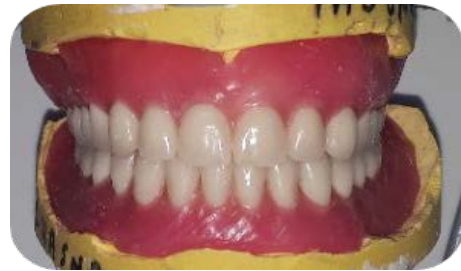

Fig.11: Mounting prosthetic teeth

• Occlusal balancing : According to Trévelo's work, adequate occlusal equilibration is accompanied by keratinization of the fibromucosa and stimulation of the bone substrate constituting a true prevention of bone resorption. (26)

+ Prosthetic bases (23) (27)

They prevent bone resorption by their extent which must encompass the entire support surface by promoting its stimulation and by their base material, the metal bases being preferable to the resin bases thanks to their low thickness, their high wettability, their biocompatibility (fewer allergic accidents or bacterial proliferation) and their good mechanical performance (transmission of osteogenic thermal shock). (Fig. 12)

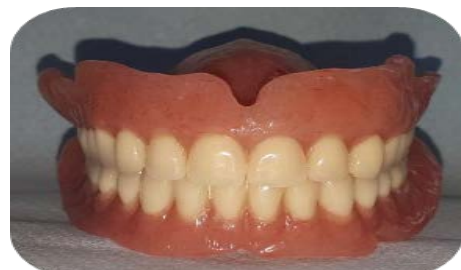

Fig. 12: Prosthetic resin base

POST-PROSTHETIC MEANS (24) (27)

Regular follow-up visits should be instituted in order to check the adaptation of the prosthetic bases, the maxillomandibular reports, the occlusion, the state of teeth and prosthetic base materials.

• Verification of occlusion and correction of excessive pressure. (Fig. 13)

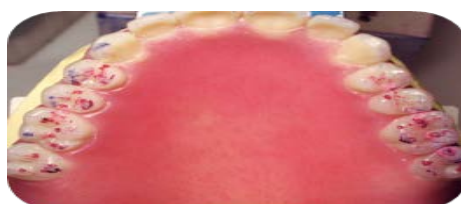

Fig. 13: Occlusal equilibration

- Rehabilitation of the bases if a hiatus appears between the lower surface of the prostheses and the underlying tissues.
- Oral hygiene recommendations to be respected: brushing of the mucous membranes, tongue, ridges, brushing of the prosthesis, weekly prosthetic disinfection, abstention from wearing the prosthesis at night.

CONCLUSION

In the short and medium term, it is possible to slow bone resorption by filling techniques, tissue regeneration. In the long term, we can only hope to preserve bone capital by maintaining necessary and sufficient stimulation. The detailed therapies and techniques regulate the management of the phenomenon of bone resorption in pre, per and post-prosthetics.

REFERENCES

- [1] Kozlova MV, Mkrtumyan AM, Belyakova AS, Dzikovitskaya LS. Features of restoration of chewing efficiency in patients over 50 years with complete absence of teeth and alveolar bone atrophy. *Adv Gerontol*. 2019;32(1-2):218-226.
- [2] Zmyslowska E, Ledzion S, Jedrzejewski K. Factors affecting mandibular residual resorption in edentulous patients : a preliminary report. *Folia Morphol* 2007; 66(3):346-52.
- [3] Carlsson Ge, Persson G. Morphologic changes in the mandible after extraction and wearing of dentures. A longitudinal clinical and X-ray cephalometric study covering 5 years. *Odontol Rev* 1967; 18: 27-54.
- [4] Cardaropoli G, Araújo M, Hayacibara R, Sukekava F, Lindhe J. Healing of extraction sockets and surgically produced - augmented and non-augmented - defects in the alveolar ridge. An experimental study in the dog. *J Clin Periodontol*. 2005 May;32(5):435-40.
- [5] Schropp L, Wenzel A, Kostopoulos L, Karring T. Bone healing and soft tissue contour changes following single-tooth extraction: a clinical and radiographic 12-month prospective study. *Int J Periodontics Restorative Dent*. 2003 Aug;23(4):313-23.
- [6] Araújo MG, Lindhe J. Dimensional ridge alterations following tooth extraction. An experimental study in the dog. *J Clin Periodontol*. 2005 Feb;32(2):212-8.
- [7] Van der Weijden F, Dell'Acqua F, Slot DE. Alveolar bone dimensional changes of post-extraction sockets in humans: a systematic review. *J Clin Periodontol*. 2009 Dec; 36(12):1048-58.
- [8] Seibert j-s., Salama h. Alveolar ridge preservation and reconstruction. *Perio* 2000 1996; 11:69-84. -55.
- [9] Hansson S, Halldin A. Alveolar ridge preservation after tooth extraction: a consequence of a fundamental principle of bone physiology. *J Dental Biomech* 2012; 3: 1-8.
- [10] Fickl S, Zuhr O, Wachtel H, Bolz W, Hürzeler M. Tissue alterations after tooth extraction with and without surgical trauma: a volumetric study in the beagle dog. *J Clin Periodontol*. 2008 Apr;35(4):356-63.
- [11] De Groot RJ, Oomens MAEM, Forouzanfar T, Schulten EAJM. Bone augmentation followed by implant surgery in the edentulous mandible: A systematic review. *J Oral Rehabil*. 2018 Apr; 45(4):334-343.
- [12] Esposito M, Brusovin MG, Coulthard P, Worthington MV. The efficacy of various bone augmentation procedures for dental implants: a cochrane systematic review of randomized controlled clinical trials. *Int J Oral Maxillofac Implants* 2006; 21(5): 696-710.
- [13] Crum RJ, Rooney GE. Alveolar bone loss in overdentures: a 5- years study. *J Prosthet Dent* 1978; 40: 610-3.
- [14] Matthys C, Vervaeke S, Besseler J, De Bruyn H. Five-year study of mandibular overdentures on stud abutments: Clinical outcome, patient satisfaction and prosthetic maintenance-Influence of bone resorption and implant position. *Clin Oral Implants Res*. 2019 Sep;30(9):940-951.
- [15] Kursoglu P, Ari N, Calikkocaoglu S. Using tissue conditioner material in neutral zone technique. *N Y State Dent J*. 2007 Jan; 73(1):40-2.
- [16] Cordaro L, Torsello F. Soft tissue conditioning by immediate restoration of immediately placed implants in full-arch rehabilitation: the double provisional technique. *Eur J Esthet Dent*. 2006 Autumn; 1(3):216-29.
- [17] Fickl S, Zuhr O, Wachtel H, Stappert CF, Stein JM, Hürzeler MB. Dimensional changes of the alveolar ridge contour after different socket preservation techniques. *J Clin Periodontol*. 2008 Oct;35(10):906-13.
- [18] Murariu-Măgureanu C, Preoteasa CT, Iosif L, Imre M, Cuculescu M, Preoteasa E. Anatomical features and prosthetic considerations of edentulous patients with mandibular reconstruction with autograft performed more than 40 years ago. *Rom J Morphol Embryol*. 2017;58(1):231-234.
- [19] Milinkovic I, Cordaro L. Are there specific indications for the different alveolar bone augmentation procedures for implant placement? A systematic review. *Int J Oral Maxillofac Surg*. 2014 May;43(5):606-25.
- [20] Gevelis MM, Lingen MW, Takemura A. Evaluation of In Situ Hardening β -Tricalcium Phosphate/Poly(lactic-co-glycolide) Bone Substitute Used in Edentulous Ridge Preservation for Late Implant Placement: Case Series. *Clin Adv Periodontics*. 2019 Jun; 9(2):55-58.
- [21] Van Waas MA et al. Differences two years after tooth extraction in mandibular bone reduction in patients treated with immediate overdentures or with immediate complete dentures. *J Dent Res*. 1993; 72: 1001-4.
- [22] Victorin L. An evaluation of bone surgery in patients with immediate dentures. *J Prosthet Dent*. 1969 Jan; 21(1):6-13.
- [23] Wyatt CC. The effect of prosthodontic treatment on alveolar bone loss: a review of the literature. *J Prosthet Dent*. 1998; 80: 362-6.
- [24] Yen YY, Lee HE, Wu YM, Lan SJ, Wang WC, Du JK, Huang ST, Hsu KJ. Impact of removable dentures on oral health-related quality of life among elderly adults in Taiwan. *BMC Oral Health*. 2015 Jan 5;15:1.
- [25] Sabir S, Regragui A, Merzouk N. Maintaining occlusal stability by selecting the most appropriate occlusal scheme in complete removable prosthesis. *Jpn Dent Sci Rev*. 2019 Nov; 55(1):145-150.
- [26] Trevelo A, Dubreuil J. Equilibration of complete removable dentures]. *Rev Odontostomatol (Paris)*. 1988 Mar-Apr; 17(2):133-60.
- [27] Matthys C, Vervaeke S, Jacquet W, De Bruyn H. Impact of crestal bone resorption on quality of life and professional maintenance with conventional dentures or Locator-retained mandibular implant overdentures. *J Prosthet Dent*. 2018 Dec;120(6):886-894.

AUTHORS' CONTRIBUTIONS

The participation of each author corresponds to the criteria of authorship and contributorship emphasized in the [Recommendations for the Conduct, Reporting, Editing, and Publication of Scholarly work in Medical Journals](#) of the [International Committee of Medical Journal Editors](#). Indeed, all the authors have actively participated in the redaction, the revision of the manuscript and provided approval for this final revised version.

COMPETING INTERESTS

The authors declare no competing interests.