

## **CASE REPORT**

# **Laryngeal Amyloidosis - A Case Report**

Mohamed Mouzouri , Adil Eabdenbitsen , Azeddine Lachkar, Mohamed Rachid Ghailan  
ENT and Maxillo-facial department, University Hospital Center Mohamed VI, Oujda, Morocco

### **ABSTRACT**

**Introduction:** laryngeal amyloidosis is an uncommon localized form of amyloidosis. The clinical symptomatology is not specific, and the diagnosis should be evoked in a persistent dysphonia.

**Case report:** A 45-year-old patient who had consulted for dysphonia lasting for 2 years. The nasofibroscopy showed an infiltrative lesion of the vocal cords. The laryngeal biopsy was performed and revealed laryngeal amyloidosis. Search for other locations were negative.

**Conclusion:** dysphonia is the most common symptom of laryngeal amyloidosis. Monitoring is extended because of the risk of recurrence and systemic dissemination.

**KEYWORDS :** Dysphonia - Larynx – Amyloidosis.

**Correspondence :** Dr Mohamed Mouzouri, ENT and Maxillo-facial department, University hospital center Mohamed VI of Oujda Morocco. BP 4806 Oujda Université 60049 Oujda, Morocco. Email: [dr.mouzouri.mohamed@gmail.com](mailto:dr.mouzouri.mohamed@gmail.com)

**Copyright © 2020** Mouzouri M et al. This is an open access article distributed under the [Creative Commons Attribution 4.0 International](https://creativecommons.org/licenses/by/4.0/), which permits unrestricted use, distribution, and reproduction in any medium, provided the original work is properly cited.

### **INTRODUCTION**

The Amyloidosis are a heterogeneous group of diseases related to an extracellular deposit of proteins capable of adopting a fibrillar abnormal conformation. They can be hereditary or acquired, localized or disseminated, asymptomatic or instead of formidable prognosis. The isolated localized Amyloidosis is rare and less than 10% of the amyloidosis, 22 cases on 236 in the series at the Mayo Clinic. Among these, laryngeal attacks are still rare [1]. We report an original case of laryngeal Amyloidosis revealed by dysphonia, and we will analyze the literature to assess clinical, therapeutic and evolving this disease features.

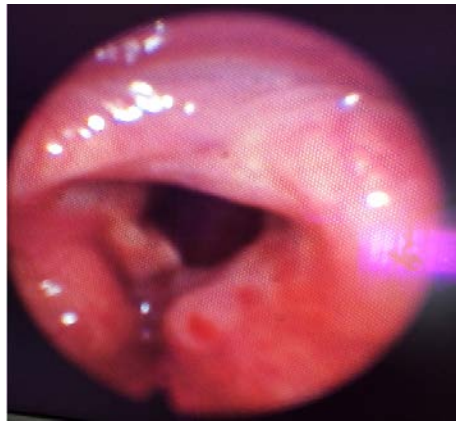
### **CASE REPORT**

We report the case of a moroccan 47-year-old female patient, unemployed. With no pathological history, including no notion of tuberculosis infection or smoking and alcoholic intoxication, who had consulted for dysphonia evolving for two years and progressive worsening. The examination found no dyspnea, dysphagia, or fever, also general State was preserved.

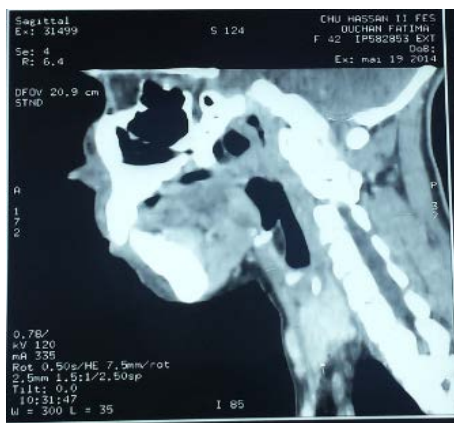The nasofibroscopy revealed an infiltration with edema of the two vocal cords with reduced mobility [figure 1]. The rest of the clinical examination was normal. Cervical scanner highlighted a thickening of the two vocal cords slightly reducing the glottic slot [figure 2].

A direct laryngoscopy done under general anesthesia has revealed an inflammatory infiltration with edema of the two vocal cords. A biopsy was performed and which was revealed at the level of the mucous chorion Eosinophilic substance Cnidaria cracked to dye red by green red congo with yellow dichroic birefringence in polarized light evoking the amyloid aspect [figure 3]. The patient was sent to the Department of internal medicine where further exploration was made (renal, kidney ultrasound, ECG, chest x-ray) finding localized laryngeal Amyloidosis.

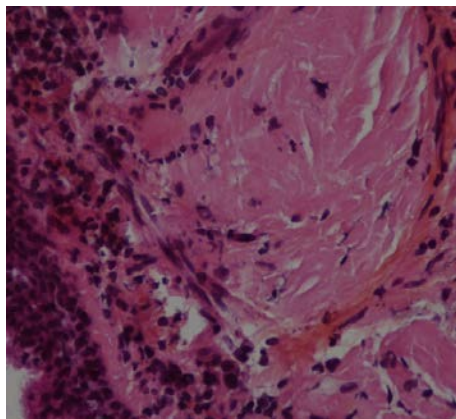
Endoscopic resection was proposed to the patient, who choose therapeutic abstention with clinical monitoring as a therapeutic strategy. Follow-up was marked by stabilization of dysphonia without dyspnea or dysphagia, and without systemic conversion of the disease.



**Fig 1:** Nasofibroscopy showing an infiltration of the vocal cords.



**Fig 2 :** Cervical scanner sagittal section showing tumor process filling the glottic floor.



**Fig 3 :** Laryngeal biopsy to dye red by congo Red.

## DISCUSSION

The Amyloidosis are related to the extracellular deposit, in different organs, diseases of an amorphous substance, amyloid, formed substance from different protein precursors. The existence of localized Amyloidosis is usually related with the production in-situ light chains which are deposited near their site of synthesis(2).

The first sighting of amylose laryngeal was reported in 1875 by Burrow and Neuman. This represents 0.17 to 1.5% of laryngees benign tumors. Laryngees attacks are usually isolated, but may be associated with nearby locations such as the cavum, tonsils, nasal or the trachea. This condition is seen especially in adults to the 4th and the 6th decade. The change of voice and dysphonia are the most frequent symptoms of laryngeal Amyloidosis. Other less frequent clinical signs have been reported: dyspnea, stridor, persistent dry cough, sleep apnea, or dysphagia. The delay between the first clinical signs and diagnosis is often long(3), in our case it was 2 years old.

Direct laryngoscopy can evoke an etiology neoplastic in front of a nodular aspect found in 44% of cases, infiltrating diffuse more or less extended essentially to the sus-glottic floor level wrongly. The diagnosis is based on the pathological examination with the color red congo where amyloid deposits appear birefringent polarised light [2,3]. The diagnosis of laryngeal Amyloidosis must seek a systemic extension before the diagnosis of a localized form. The balance sheet must search for a kidney, heart or skin damage (4).

The treatment of localized forms includes mainly local surgical gestures, by the microinstruments or laser excision. The risk of recidivism is low after complete resection. However, the surgical gestures seldom realize complete amyloid deposits mainly destruction to sub-glottic locations (5).

## CONCLUSION

The laryngeal Amyloidosis is a rare localized form of Amyloidosis. The diagnosis is often late. Dysphonia is the most common symptom. Direct laryngoscopy allows the local assessment of extension and a biopsy confirming the diagnosis. Clinical and biological monitoring should be extended due to late local recurrences and possible systemic dissemination.

## ACKNOWLEDGEMENTS

We are very thankful to Mrs Briksi Naima for her precious help.

## AUTHORS' CONTRIBUTIONS

The participation of each author corresponds to the criteria of authorship and contributorship emphasized in the [Recommendations for the Conduct, Reporting, Editing, and Publication of Scholarly work in Medical](#)

[Journals](#) of the [International Committee of Medical Journal Editors](#). Indeed, all the authors have actively participated in the redaction, the revision of the manuscript and provided approval for this final revised version.

## COMPETING INTERESTS

The authors declare no competing interests.

**REFERENCES**

- [1] Vignes S, Brasnu D, Hénégar C, Tiev KP, Généreau T, Cabane J. Amylose laryngée: Une cause rare de dysphonie. *Rev Med Interne*. 2000;21(12):1121–5. DOI: [10.1016/s0248-8663\(00\)00272-1](https://doi.org/10.1016/s0248-8663(00)00272-1)
- [2] Kharrat S, Besbes G, Trabelsi S, Lachkham A, Mekni A, Zainine R, et al. L'amylose Laryngée À Propos D'un Cas. *J Tunisien d'ORL Chir Cervico-Faciale*. 2006 Aug 26;16(1):30–1. DOI: [10.4314/jtdorl.v16i1.42058](https://doi.org/10.4314/jtdorl.v16i1.42058)
- [3] Thompson LDR, Derringer GA, Wenig BM. Amyloidosis of the larynx: A clinicopathologic study of 11 cases. *Mod Pathol*. 2000;13(5):528–35. DOI: [10.1038/modpathol.3880092](https://doi.org/10.1038/modpathol.3880092)
- [4] Ayadhi oueslati Z, Ben azzouna H, Toumi S et al. Amylose laryngée à propos d'un cas. *J Tun ORL*. 2001;07:36-9.
- [5] Talbot AR. Laryngeal amyloidosis. *J Laryngol Otol*. 1990 Feb;104(2):147–9. DOI: [10.1017/s0022215100112113](https://doi.org/10.1017/s0022215100112113)