

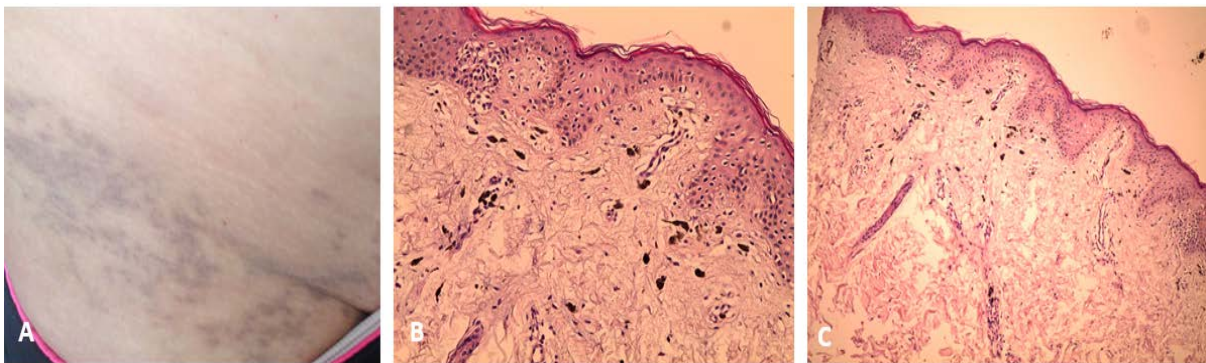
***IMAGES IN CLINICAL MEDICINE***

**ASHY DERMATOSIS: A CASE OF CINDERELLA**

Dr Zaouri Hasnaa MD, Pr Hassam Baderddine MD.  
Department of Dermatology, Ibn Sina University Hospital, Rabat.

*Received 08 Septembre 2015; Revised 17 Septembre 2015; Accepted 20 Septembre 2015.*

**KEY WORDS:** Ashy dermatosis , Erythema perstans dyschromicum , Hypermelanosis.



We report the case of a 20-years old female, who presented an asymptomatic grayish macules affecting the neck, trunk and roots of legs (Panel A). Histopathologic examination showed an increased dermal melanophages (Panel B) and a vacuolization of basal cell layer (Panel C), evoking an ashy dermatosis (AD). Paraclinical assessment didn't find any related disease. Multiple therapy was proposed such as corticosteroids and phototherapy. Evolution was marked by the extension of lesions in members at five years of follow-up.

AD was first described by Ramírez. He called the patients «Los cenicientos». The Spanish term cenicienta means Cinderella, because of this folklore character's close association with ashes from sitting at home alone by the fireplace. Most cases present gray-brown macules which are commonly found on the face, arms, neck, and trunk. Histopathologic findings are nonspecific and include vacuolization of the basal layer, pigmentary incontinence and perivascular inflammatory infiltrate. The etiology of AD is unknown. Some authors reported associations with ammonium nitrate, whipworm infestation and HIV seroconversions. Many treatments was proposed such as corticosteroids, dapsone, clofazimine and phototherapy, but the results are not satisfactory. Such as basic research on the pathogenesis and treatment of hypermelanosis continuous, we look for more answers to the questions raised by this case.

**Corresponding author:**

Dr Hasnaa Zaouri, Department of Dermatology, Ibn Sina University Hospital, Rabat, Morocco.  
Email: [hasnaazaouri@yahoo.fr](mailto:hasnaazaouri@yahoo.fr)

**Copyright © 2015 Hasnaa Zaoui et al.**

This is an open access article distributed under the [Creative Commons Attribution License](https://creativecommons.org/licenses/by/4.0/), which permits unrestricted use, distribution, and reproduction in any medium, provided the original work is properly cited.