


RESEARCH ARTICLE

Role of Multidetector CT in Evaluation of Benign Focal Liver Lesions in a Tertiary Care Centre in North India

Dr. Tarun Narang ^a , Dr. Shweta ^b, Dr. Chiranjeew Gathwal ^c, Dr. shailley ^d

^a Assistant professor Department of Radio diagnosis BPS GMC {W} Khanpur kalan , sonipat , Haryana.

^b Associate Professor, Department of physiology, N.C. Medical college and hospital , Panipat , Haryana.

^c Associate Professor, Department of Radio diagnosis , BPS GMC { W } , Khanpur Kalan , Sonipat, Haryana.

^d Assistant professor, Dept of Radiation oncology , PGIMS Rohtak , Haryana.

ABSTRACT

Introduction: Introduction of Multi Detector computed Tomography has been a huge leap in the CT technology. MDCT has a high diagnostic accuracy, sensitivity and specificity in the evaluation of focal and diffuse lesions of liver. The present study aimed to study the role of MDCT as a diagnostic modality for the benign lesions of liver. **Material and methods:** A prospective study of the role of MDCT in detecting and characterizing neoplastic hepatic lesions was conducted in the period in radiology department of RMCH, Bareilly. Thirty patients, with hepatic benign lesions, were selected. Diagnosis was confirmed by surgery and histopathology, follow up imaging and other non-radiological investigations. **Results:** Thirty patients were finally included as they were found to have benign lesions. Mean age of the patients was 49.8 years. 37% patients aged between 41 and 50 years while 17% patients were elderly. 63% were females. 63% patients had alcohol abuse while 60% were smokers. The most common presenting complaint was pain abdomen (n=15) followed by abdominal discomfort (n=13). Total of 29 lesions were identified on MDCT. The most common lesions were hemangioma (n=15) (Figure 1) followed by simple cyst (n=5). **Conclusion:** MDCT is “The Imaging Modality of choice” in characterizing benign hepatic lesions.

Keywords: Multidetector CT ; Focal liver lesions.

Correspondence: Dr. Tarun Narang. Assistant Professor, Department of Radio diagnosis , C-48, Medical Campus BPS GMC { W } Khanpur kalan , Sonipat Haryana – 131305. Mail address :- tarunnarang24@gmail.com

Copyright © 2020 Tarun N. et al. This is an open access article distributed under the [Creative Commons Attribution 4.0 International](https://creativecommons.org/licenses/by/4.0/), which permits unrestricted use, distribution, and reproduction in any medium, provided the original work is properly cited.

INTRODUCTION

The Liver, due to its major function of detoxification and its rich blood supply by hepatic artery and portal vein becomes prone to various diseases and pathologic alterations. The practice for liver imaging has undergone a significant change over the past two decades. The conspicuity of a liver lesion on CT depends on the attenuation difference between the lesion and the normal liver. Only a minority of liver lesions that contain calcifications, cystic components, fat or hemorrhage can be detected by a non-enhanced CT scan. Multiphase CT is an effective aid in determining the number, location, and nature of focal liver lesions and monitoring their size over time. In patients with cancer, it is also helpful in detecting metastatic lesions. In the blood supply of liver, 80% of normal liver parenchyma is supplied by the portal vein and 20% by the hepatic artery. The difference in blood supply results in different enhancement patterns between various liver lesions in the various phases of contrast enhancement (1).

The innovation of Multidetector Computed Tomography (MDCT) is the advancement in CT technology that involves the use of a multiple-row detector array instead of the traditional single-row detector array used in spiral CT. This new innovation helps in scanning four to eight times faster as compared to spiral CT [2]. Images of the entire liver in arterial, portal, and equilibrium phases may be taken with triphasic spiral CT technique [3,4]. CT has become an ideal imaging modality because it is readily available and has short scanning time [5,6]. Combination of arterial phase imaging along with portal venous imaging has improved the detection of lesions especially in hypervascular neoplasms [7-10]. Most sensitive is the portal phase for lesion detection whereas additional information on vascularity of the lesion may be gained with the help of arterial and equilibrium phases [5-9].

To attain a correct diagnosis, multiple modalities in radiological imaging along with histopathological

characteristics and clinical assessment are used [11]. In the available literature, especially in India there are fewer comprehensive studies about the role of multiphase MDCT scan in characterising liver lesions under benign or malignant category. With the above background, this study was undertaken as an effort to assess the role of MDCT in detection and characterisation of focal benign liver lesions and help in deciding further course of management.

MATERIALS AND METHODS

The present study was conducted in the Department of Radiodiagnosis, RMCH, Bareilly. Data for the study was collected from 30 patients attending the Department of surgery with clinically suspected focal liver lesions, or previous images depicted focal hepatic lesions with non specific appearance detected clinically or sonographically. The patients were included if they showed clinical suspicion of focal liver lesions, and/or previous imaging studies depicted focal liver lesions with non specific appearance. All patients with history of trauma and allergic to contrast agents were excluded from the study.

Triphasic CT imaging technique of liver

Patients were kept fasting 4 hours prior to the CT scan to avoid complications while administering contrast medium. Risks of contrast administration were explained to the patients and consent was obtained prior to the contrast study. Routine antero posterior topogram of the abdomen as initially taken in all patients in the supine position with the breath held. Axial sections of 5mm thickness were taken from the level of lung bases to the level of ischial tuberosities. In all the cases, plain scan was followed by intravenous contrast scan in suspended inspiration.

For contrast enhancement, 18G Vasofix (indwelling catheter) was placed in antecubital vein and dynamic injection at a rate of about 3-5 ml/sec of non-ionic contrast material (omnipaque 350 mg iodine/ml) were given initially. Sections were taken in HAP (20-30s), PVP (60s) and delayed (3-5 minutes) phases in cranio caudal direction from the superior margin to the inferior border of the liver.

Image interpretation

Dynamic viewing of all reconstructed images was done. First, the unenhanced, HAP and PVP images were reviewed for the presence of focal liver lesions. Second, the CT appearance of each lesion in each phases (unenhanced HAP, PVP and delayed images) was characterized based on enhancement patterns and its attenuation compared with that of the liver parenchyma in that phase.

Lesions were broadly grouped as hypervascular lesions relative to the surrounding parenchyma or, as hypovascular lesions compared with the surrounding parenchyma.

Images of different phases were analyzed separately and later were reinterpreted together. Later the lesions were confirmed by Fine needle aspiration cytology /biopsy / USG / surgery / follow-up as and when required. In some patients with multiple lesions biopsy was performed on only two lesions, rest with similar CT appearance were assumed as the same lesion. If the lesion did not show any change in size after minimum of six months then the lesion was presumed to be benign.

If the number of lesions were >10 then analysis of 10 most representative lesions were performed using the combination of all the phases.

Appearance of each lesion in each phase was described on the basis of attenuation and homogeneity of the lesion in comparison to the liver parenchyma in that phase.

The pattern of enhancement was a three-pattern name that includes appearance of lesion in each phase e.g. (hypo/hypo/hypo).

Additional patterns of subtype enhancement in arterial phase like peripheral puddles, variegated, continuous hyperattenuating rim, incomplete rim and cleft were also considered.

Data were presented as frequency and percentages

RESULTS

Thirty patients were finally included as they were found to have benign lesions. Mean age of the patients was 49.8 years. 37% patients aged between 41 and 50 years while 17% patients were elderly, 63% were females, 63% patients had alcohol abuse while 60% were smokers. The most common presenting complaint was pain abdomen (n=15) followed by abdominal discomfort (n=13) (Table 1).

Table 1: General characteristics

| | Frequency | Percentages |
|------------------------------|-----------|-------------|
| Age (years) | | |
| 21-30 | 1 | 3.3 |
| 31-40 | 6 | 20.0 |
| 41-50 | 11 | 36.7 |
| 51-60 | 7 | 23.3 |
| >60 | 5 | 16.7 |
| Sex | | |
| Male | 11 | 36.7 |
| Female | 19 | 63.3 |
| Past history | | |
| Smoking | 18 | 60 |
| Alcohol | 19 | 63 |
| Presenting complaints | | |
| Pain abdomen | 15 | 50.0 |
| Abdominal discomfort | 13 | 43.3 |
| Anorexia | 9 | 30.0 |
| Fever | 8 | 26.7 |
| Weight loss | 5 | 16.7 |

Table 2: Various type of lesions

| | Number of lesions |
|--------------|-------------------|
| Abscess | 3 |
| Adenoma | 1 |
| FNH | 3 |
| Hemangioma | 15 |
| Hydatid cyst | 2 |
| Simple cyst | 5 |

Type of focal liver lesions

Table 2 showed various types of lesions on MDCT. Total of 29 lesions were identified on MDCT. The most common lesions were hemangioma (n=15) (Figure 1) followed by simple cyst (n=5) (Figure 2).

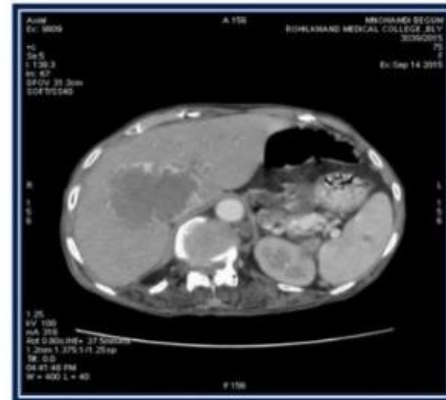
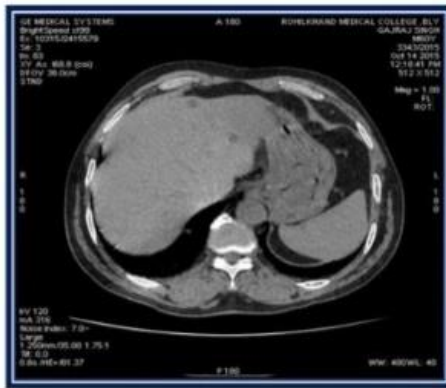
Figure 1: Hemangioma in unenhanced phase and HAP

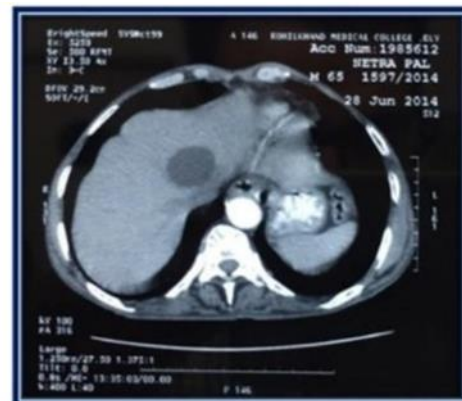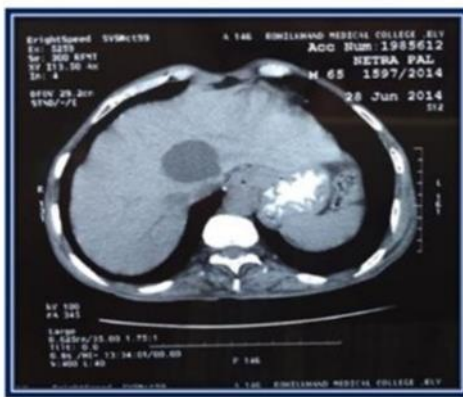


Figure 2: Simple cyst in unenhanced phase and HAP

DISCUSSION

Imaging of the liver with the help of Multidetector CT scan is a common procedure in the current era. It is recommended to do scanning using triple-pass technique, highlighting the arterial, parenchymal, and portal venous phases.

. Multidetector CT help in the acquisition of very thin sections over a large area of an organ and also permits scanning during multiple specific phases of intravenous contrast enhancement allowing the creation of multiplanar reconstructions with high z-axis resolution.

The most common age group affected in our study was 41 to 70 years. It is in concordance with study by Patel et al [12]. Hepatic cysts are common benign liver lesions that occur in 2%–7% of the population. These lesions may be isolated or multiple and vary from a few millimetres to several centimetres in diameter [13]. On non enhanced CT scans, A hepatic cyst appears as a homogeneous and hypoattenuating lesion, and after administration of contrast material, there is no enhancement of its wall or content [14]. In our study, there were 5 lesions of simple cysts.

Hepatic haemangioma are the most common benign hepatic tumour and are found incidentally at routine radiologic examinations such as sonography and CT scan at rate of 5- 20% [15,16]. On nonenhanced CT scan, The typical haemangioma appears as a hypoattenuating lesion, and in arterial phase, early peripheral nodular enhancement is seen. The attenuation of the peripheral nodules is similar to that of the adjacent aorta [17]. In venous phase, centripetal enhancement is seen which progresses to uniform filling in the delayed phase [18,19].

CONCLUSION

In recent decades, MDCT has become the mainstay for diagnosis of hepatic lesions because of its ease, availability, cost effectiveness, less time consumption, ability to reveal

anatomy of structures, extent of the disease process and most importantly, guiding the surgeons to plan surgery accordingly.

The results of this study prove MDCT to be highly sensitive in sorting the hepatic lesions into clinically relevant categories which helps in achieving correct diagnosis and evaluation of lesion. This study opens new possibilities of prevention of liver disease with early detection and consequent management of hepatic lesions.

ACKNOWLEDGMENTS

None.

COMPETING INTERESTS

The authors declare no competing interests with this case.

FUNDING SOURCES

None.

AUTHORS' CONTRIBUTIONS

The participation of each author corresponds to the criteria of authorship and contributorship emphasized in the [Recommendations for the Conduct, Reporting, Editing, and Publication of Scholarly work in Medical Journals of the International Committee of Medical Journal Editors](#). Indeed, all the authors have actively participated in the redaction, the revision of the manuscript, and provided approval for this final revised version.

REFERENCES

- [1] Hussain SM, Semelka RC. Hepatic Imaging: Comparison of modalities Radiol Clin North Am 43.(2005) sep ; 43(5)929 – 47 .
- [2] Berland LL, Smith JK. Multi-detector array CT: once again, technology creates new opportunities (editorial). Radiology. 1998;20(9):327-29.
- [3] Bonaldi VM, Bret PM, Reinhold C, Atri M. Helical computed tomogram of liver, value of an early hepatic arterial phase. Radiology. 1995;19(7):357-63.
- [4] Francis IR, Cohan RH, McNulty NJ, Platt JF, Korobkin M, Gebremariam A, et al. Multi-detector CT of the liver and hepatic neoplasms: Effect of multiphase imaging on tumor conspicuity and vascular enhancement. AJR Am J Roentgenol. 2003;18(1):1217-24.
- [5] Ichikawa T, Saito K, Yoshioka N, Tanimoto A, Gokan T, Takehara Y, et al. Detection and characterization of focal liver lesions: A Japanese phase III, multicenter comparison between gadoxetic acid disodium enhanced magnetic resonance imaging and contrast enhanced computed tomography predominantly in patients with hepatocellular carcinoma and chronic liver disease. Invest Radiol. 2010;4(5):133-41.
- [6] Hammersting R, Huppertz A, Breuer J, Balzer T, Blakeborough A, Carter R, et al. Diagnostic efficacy of gadoxetic acid (Primovist)-enhanced MRI and spiral CT for a therapeutic strategy: Comparison with Intraoperative and histopathologic findings in focal liver lesions. Eur Radiol. 2008;1(8):457-67.
- [7] Soyer P, Sirol M, Fargeaudou Y, Duchat F, Hamzi L, Boudiaf M, et al. Differentiation between true focal liver lesions and pseudolesions in patients with fatty liver: evaluation of helical CT criteria. Eur Radiol. 2010;20(1):1726-37.
- [8] Van Leeuwen MS, Noordzij J, Feldberg MA, Hennipman AH, Doorneewaard H. Focal Liver lesions; characterization with tri-phasic computed tomography. Radiology. 1996;20(1):327-36.
- [9] Szklaruk J, Silverman PM, Chamsangavej C. Imaging in the diagnosis, staging, treatment and surveillance of hepatocellular carcinoma. AJR Am J Roentgenol. 2003;18(1):441-54.
- [10] Iannaccone R, Piacentini F, Murakami T, Paradis V, Belghiti J, Hori M, et al. Hepatocellular carcinoma in patients with non-alcoholic fatty liver disease: Helical CT and MR imaging findings with clinical-pathologic comparison. Radiology. 2007;24(3):422-30.
- [11] Tyagi V, Sahoo K, Shaha P, Tyagi N, Thite H, Aggarwal D, et al. Evaluation of liver masses with 16 slice multi-detector computed tomography with pathological correlation. JMSCR. 2018;06(01):32033-45.
- [12] Kalpesh K. Patel, Mayur V. Khandhedha, Vishalkumar H. Bhardava. Multi-detector CT evaluation of liver neoplasms. International Journal of Contemporary Medicine Surgery and Radiology. 2018;3(3):C158-C163
- [13] Horton, K. M., Bluemke, D. A., Hruban, R. H., Soyer, P., and Fishman, E. K. CT and MR Imaging of Benign Hepatic and Biliary Tumors. RadioGraphics, 1999; 19(2): 431–451.
- [14] Mathieu, D., Vilgrain, V., Mahfouz, A. E., Anglade, M. C., Vullierme, M. P., and Denys, A. Benign liver tumors. Magnetic Resonance Imaging Clinics of North America 1997;5(2):255–288
- [15] Ishak KG, Rabin L. Benign tumors of the liver. Med Clin North Am 1975; 59:995-1013. [16]. Brannigan M, Burns PN, Wilson SR. Blood flow patterns in focal liver lesions at microbubble-enhanced US. RadioGraphics 2004; 24(3):921-935.
- [16] Soyer, P., Dufresne, A. C., Somveille, E., and Scherrer, A. Hepatic cavernous hemangioma: Appearance on T2-weighted fast spin-echo MR imaging with and without fat suppression. AJR Am J Roentgenol. 1997;168(2):461-5.
- [17] Nelson RC, Chezmar JL. Diagnostic approach to hepatic hemangiomas. Radiology 1990; 176(3):11-13.
- [18] Leslie DF, Johnson CD, MacCarty RL, Ward EM, Ilstrup DM, Harmsen WS. Single-pass CT of hepatic tumors: value of globular enhancement in distinguishing hemangiomas from hypervascular metastases. Am J Roentgenol 1995; 165(5):1403-1406.