

CASE REPORT

Non-Syndrome Case of Multiple Erupted Supernumerary Teeth and Wisdom Tooth Anodontia

Nawaf Alzaben ^a, Husein Alomer ^b, Yousef Tashkandi ^c

^a Graduate Resident in Advanced General Dentistry Program, Prince Abdulrahman Advanced dental Institute, Riyadh, Saudi Arabia

^b Restorative Dentistry Consultant, Head Restorative Dentistry Dept., Prince Abdulrahman Advanced dental Institute, Riyadh, Saudi Arabia

^c Orthodontist Consultant, Orthodontics Dept. Prince Abdulrahman Advanced dental Institute, Riyadh, Saudi Arabia

ABSTRACT

Supernumerary teeth can be detected during a routine clinical or radiographic examination. They are defined as any tooth or tooth substances that are excess of the usual configuration of twenty deciduous and thirty-two permanent teeth. Supernumerary teeth can cause several complications. It depends on the location or stage of their formation, such as: preventing or delaying the eruption of associated permanent teeth, crowding or malocclusion. The main aim of orthodontic treatment of supernumerary teeth is to restore adequate dental aesthetics and functions. After the clinical, radiographic and tomographic diagnosis, the orthodontic treatment of supernumerary teeth will depend on several factors. Such as; the location, proximity to vital anatomical structures, space availability in the arch, shape and the amount of supporting periodontal tissue. Reports in Western Region in Saudi Arabia showed that the range of the prevalence of supernumerary teeth was 0.1–3.8% of the population. The current finding, however, was 0.3%, a finding that is not in concert with what was reported by Fardi et al. in which the prevalence of supernumerary teeth was 1.8%.

This case reported a unilateral four premolars erupted to occlusion in the right mandibular arch for non-syndrome patient.

KEYWORDS: Non-Syndrome Case, Multiple Erupted Supernumerary Teeth, Wisdom Tooth Anodontia.

Correspondence: Dr Husein Alomer. Restorative Dentistry Consultant, Head Restorative Dentistry Dept. Prince Abdulrahman Advanced dental Institute, Riyadh, Saudi Arabia. Email: dr.alomer@yahoo.com

Copyright © 2021 Alzaben N et al. This is an open access article distributed under the [Creative Commons Attribution 4.0 International](https://creativecommons.org/licenses/by/4.0/), which permits unrestricted use, distribution, and reproduction in any medium, provided the original work is properly cited.

INTRODUCTION

Supernumerary teeth can be detected during a routine clinical or radiographic examination. They are defined as any tooth or tooth substances that are excess of the usual configuration of twenty deciduous and thirty-two permanent teeth (1).

PREVALENCE

The prevalence of hyperdontia teeth in primary dentition is low, because it is generally overlooked by the parents. If it occurs, it is often of normal shape (supplemental type), erupt normally, and appear to be in proper alignment (2). Rajab and Hamdan reported in their study conducted in Jordan that males were more commonly affected than females; the ratio being 2.2:1 (5).

Supernumerary teeth are estimated to occur 8.2 times more frequently in maxilla than mandible (6,7,8) and commonly affect the premaxilla (23). Multiple supernumerary teeth are commonly found in the mandibular premolar region (10).

Reports in Western Region in Saudi Arabia showed that the range of the prevalence of supernumerary teeth was 0.1–3.8% of the population. The current finding, however, was 0.3%, a finding that is not in concert with what was reported by Fardi et al. in which the prevalence of supernumerary teeth was 1.8%.

Several studies reported the incidence of the supernumerary teeth in different populations. Bäckman and Wahlin conducted a clinical study by examining 739 Caucasian children and found 14 cases (1.9%) of at least one supernumerary tooth, and the majority of the supernumerary teeth reported were mesiodens. Salem investigated the incidence of supernumerary teeth in a sample of 2,393 Saudi Arabian children and found that only 0.5% sample studied had at least one supernumerary tooth.

Several investigators indicated a higher prevalence of supernumerary teeth in males compared to females. In this study the male-to-female ratio was 1 : 2, which is in accord with the ratio reported for the Caucasians but in

disagreement with the ratios reported in other studies. This could be due to the small number of observed supernumerary cases (i.e., 2 females and one male).⁽²⁴⁾

ETIOLOGY

The etiology of supernumerary teeth is not completely understood. There are multiple theories behind the different types of supernumerary teeth. One of them suggests that they are created as a result of a dichotomy of the tooth bud (3). Other studies have reported that they are the result of hyperactivity of the dental lamina where the epithelial cells that form supernumerary teeth remain for long periods (25).

In a survey of 2,000 schoolchildren, Brook found that supernumerary teeth were present in 0.8% of primary dentitions and in 2.1% of permanent dentition (4).

While Phylogenetic theory, has been discounted as it would only explain single anomalies of ectopic teeth. the

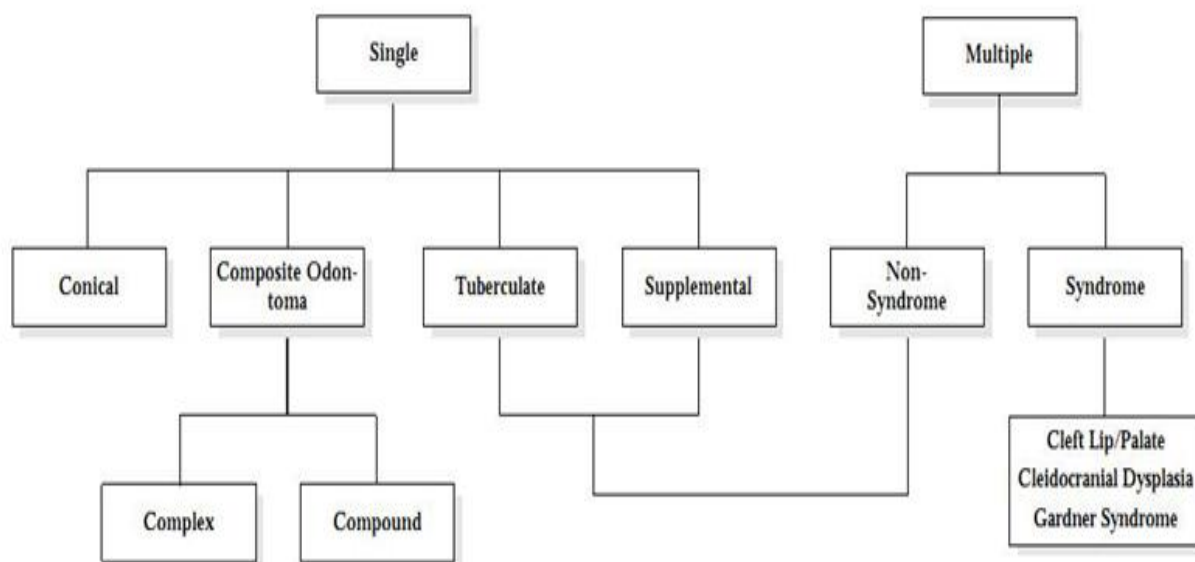
main etiological factor is genetic predisposition, associated with a dominant autosomal gene with Several developmental disorders that may have multiple supernumerary teeth such as: Cleft lip and palate, Cleidocranial dysostosis, and Gardner's syndrome. Other associated syndromes include Fabry - Anderson's syndrome or chondroectodermal dysplasia, Rothmund - Thompson syndrome and Nance - Horan syndrome (13-22)

CLASSIFICATION

Supernumerary teeth can be classified according to morphology, chronology, orientation and location (**Table 1**). The morphology in primary dentition is usually normal or conical, while in permanent dentition it's with greater variety of forms. Four different morphological types of supernumerary teeth have been described ^(11, 12).

Table 1

Classification of Supernumeraries



COMPLICATION

Supernumerary teeth can cause several complications. It depends on the location or stage of their formation, such as: preventing or delaying the eruption of associated permanent teeth, crowding or malocclusion, incomplete space closure during orthodontic treatment, dilaceration, delayed or abnormal root development of associated permanent teeth, root resorption of adjacent teeth, cyst formation, and it may migrate into the nasal cavity, maxillary sinus or hard palate ⁽¹³⁻²²⁾.

CASE REPORT

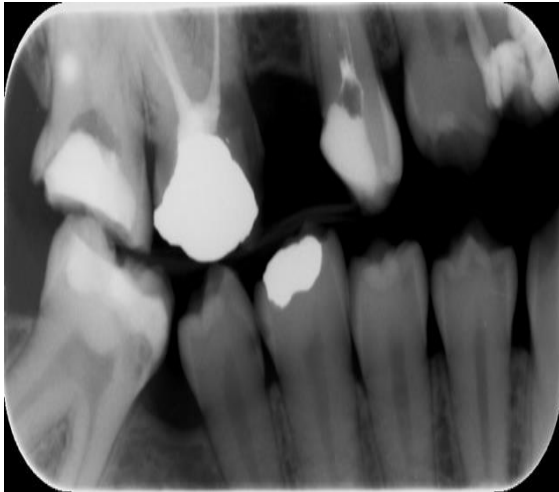
19 years old young female patient came to Prince Abdularahman advanced Dental Institute clinic complaining from pain in her lower left area.

All patient personal data, history, extra oral and Intra oral examinations were done. The medical history of the patient has revealed neither medical problems nor any syndromic conditions. And has no relative family medical problems. The dental diagnosis of her chief complaint

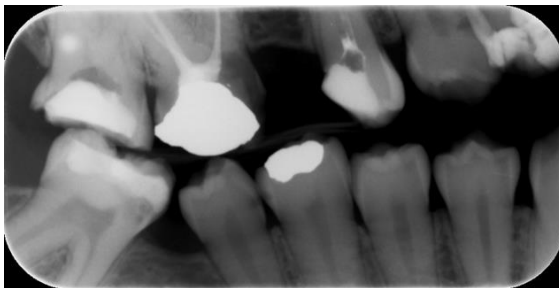was irreversible pulpitis in tooth #34. Poor oral hygiene with multi carious lesions, defective restorations and previously initiated root canal therapy were also detected, addressed and planned to be treated

Additional clinical findings were noticed, in which she has multiple supernumerary teeth in her lower right arch. Patient was referred to the Orthodontic department for additional assessment and treatment. She has two supernumerary teeth distal to lower second premolar #45. Tooth #46 was extracted many years ago due to extensive caries.

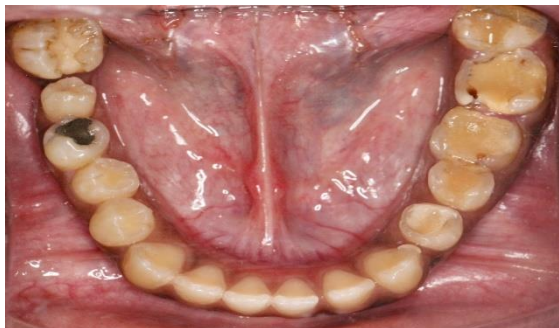The main aim of orthodontic treatment of supernumerary teeth is to restore adequate dental aesthetics and functions. After the clinical, radiographic and tomographic diagnosis, the orthodontic treatment of supernumerary teeth will depend on several factors. Such as; the location, proximity to vital anatomical structures, space availability in the arch, shape and the amount of supporting periodontal tissue.



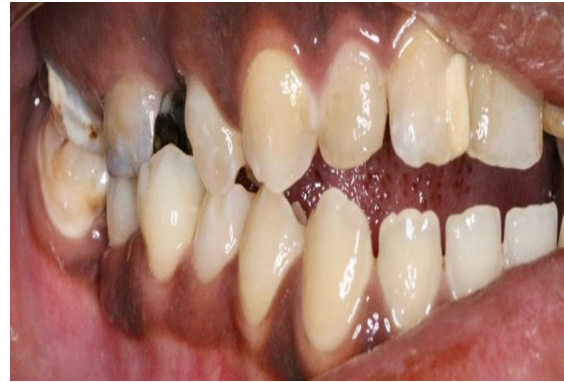OPG - shows 4 Erupted Premolars in the Mandibular Right Side, Mesial Tipping of Tooth #47 due to Early Extraction of tooth #46. Wisdom Tooth Is Missing



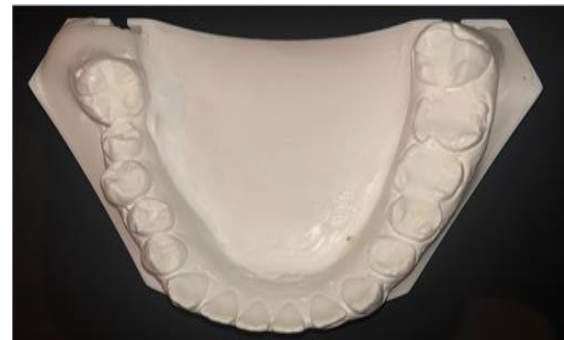Bite-Wing Radiograph Showing the Erupted 4 Premolars



Clinical Occlusal View – Mandibular Arch



Lateral view – Mandibular Right Side



Occlusal View of Diagnostic Cast – Mandibular Arch

CONCLUSION

The treatment of cases with supernumerary teeth depends on several factors such as location and their alignment within the arch. Orthodontic treatment may be indicated with presence of adequate spaces. Otherwise extraction is the appropriate treatment to prevent any future complications.

AUTHORS' CONTRIBUTIONS

The participation of each author corresponds to the criteria of authorship and contributorship emphasized in the [Recommendations for the Conduct, Reporting, Editing, and Publication of Scholarly work in Medical Journals of the International Committee of Medical Journal Editors](#).

PATIENT CONSENT

Written informed consent was obtained from the patient for the publication of this case report.

REFERENCES

- [1] L. Mitchell. Supernumerary teeth. *Dent Update*. 1989 Mar;16(2):65-6, 68-9. Available: <https://pubmed.ncbi.nlm.nih.gov/2599248>
- [2] Scheiner MA, Sampson WJ. Supernumerary teeth: A review of the literature and four case reports. *Aust Dent J*. 1997;42(3):160-5
DOI: [10.1111/j.1834-7819.1997.tb00114.x](https://doi.org/10.1111/j.1834-7819.1997.tb00114.x)
- [3] Liu JF. Characteristics of premaxillary supernumerary teeth: a survey of 112 cases *ASDC J Dent Child*. Jul-Aug 1995;62(4):262-5. Available: <https://pubmed.ncbi.nlm.nih.gov/7593884/>
- [4] Brook AH. Dental anomalies of number, form and size: their prevalence in British schoolchildren. *J Int Assoc Dent Child*. 1974 Dec;5(2):37-53. Available: <https://pubmed.ncbi.nlm.nih.gov/4535299/>
- [5] Rajab LD, Hamdan MA. Supernumerary teeth: Review of the literature and a survey of 152 cases. *Int J Paediatr Dent* 2002;12:244-54.
DOI: [10.1046/j.1365-263x.2002.00366.x](https://doi.org/10.1046/j.1365-263x.2002.00366.x)
- [6] Stafne EC. Supernumerary teeth. *Dent Cosmos*. 1932;74:653-9.
- [7] Açıkgöz A, Açıkgöz G, Tunga U, Otan F. Characteristics and prevalence of nonsyndromic multiple supernumerary teeth: A retrospective study. *Dentomaxillofac Radiol*. 2006;35:185-90.
DOI: [10.1259/dmfr/21956432](https://doi.org/10.1259/dmfr/21956432)
- [8] Hall A, Onn A. The development of supernumerary teeth in the mandible in cases with a history of supernumeraries in the pre-maxillary region. *J Orthod*. 2006;33(4):250-5.
DOI: [10.1179/146531205225021735](https://doi.org/10.1179/146531205225021735)
- [9] Koch H, Schwartz O, Klausen B. Indications for surgical removal of supernumerary teeth in the premaxilla. *Int J Oral Maxillofac Surg*. 1986;15(3):273-81.
DOI: [10.1016/s0300-9785\(86\)80085-0](https://doi.org/10.1016/s0300-9785(86)80085-0)
- [10] Shah A, Gill DS, Tredwin C, Naini FB. Diagnosis and management of supernumerary teeth. *Dent Update*. 2008;35(8):510-2, 514-6, 519-20.
DOI: [10.12968/denu.2008.35.8.510](https://doi.org/10.12968/denu.2008.35.8.510)
- [11] Mitchell L. *An Introduction to Orthodontics*. 1st ed. Oxford University Press; 1996. p. 23-5.
- [12] Andlaw RJ, Rock WP. *A Manual of Paediatric Dentistry*. 4th ed. New York: Churchill Livingstone; 1996. p. 156.
- [13] Rajab LD, Hamdan MA. Supernumerary teeth: Review of the literature and a survey of 152 cases. *Int J Paediatr Dent* 2002;12:244-54.
DOI: [10.1046/j.1365-263x.2002.00366.x](https://doi.org/10.1046/j.1365-263x.2002.00366.x)
- [14] Liu JF. Characteristics of premaxillary supernumerary teeth: A survey of 112 cases. *ASDC J Dent Child* 1995;62:262-5. Available: <https://pubmed.ncbi.nlm.nih.gov/7593884/>
- [15] Bodin I, Julin P, Thompson M, Hyperdantia I. Frequency and distribution of supernumerary teeth among 21,609 patients. *Dentomaxillofac Radiol*. 1978;7(1):15-7.
DOI: [10.1259/dmfr.1978.0002](https://doi.org/10.1259/dmfr.1978.0002)
- [16] Zmener O. Root resorption associated with an impacted mesiodens: A surgical and endodontic approach to treatment. *Dent Traumatol*. 2006;22(5):279-82.
DOI: [10.1111/j.1600-9657.2006.00355.x](https://doi.org/10.1111/j.1600-9657.2006.00355.x)
- [17] Sian JS. Root resorption of first permanent molar by a supernumerary premolar. *Dent Update*. 1999 Jun;26(5):210-1
DOI: [10.12968/denu.1999.26.5.210](https://doi.org/10.12968/denu.1999.26.5.210)
- [18] Parry RR, Iyer VS. Supernumerary teeth amongst orthodontic patients in India. *Br Dent J* 1961;111:257-8.
- [19] Garvey MT, Barry HJ, Blake M. Supernumerary teeth - an overview of classification, diagnosis, and management. *J Can Dent Assoc*. 1999;65(11):612-6. Available: <http://www.cda-adc.ca/jcda/vol-65/issue-11/612.html>
- [20] Shah A, Gill DS, Tredwin C, Naini FB. Diagnosis and management of supernumerary teeth. *Dent Update* 2008;35:510-520, 514-6, 519-20.
DOI: [10.12968/denu.2008.35.8.510](https://doi.org/10.12968/denu.2008.35.8.510)
- [21] Tyrologou S, Koch G, Kurol J. Location, complications and treatment of mesiodentes: A retrospective study in children. *Swed Dent J*. 2005;29(1):1-9. Available: <https://pubmed.ncbi.nlm.nih.gov/15898358/>
- [22] Shah A, Hirani S. A late-forming mandibular supernumerary: A complication of space closure. *J Orthod* 2007;34:168-72.
DOI: [10.1179/146531207225022149](https://doi.org/10.1179/146531207225022149)
- [23] Amaral D, Muthu M S. Supernumerary teeth: Review of literature and decision support system. *Indian J Dent Res* 2013;24:117-22
DOI: [10.4103/0970-9290.114911](https://doi.org/10.4103/0970-9290.114911)
- [24] Ahmed R. Afify, Khalid H. Zawawi. The Prevalence of Dental Anomalies in the Western Region of Saudi Arabia. *I ISRN Dent*. 2012;2012:837270.
DOI: [10.5402/2012/837270](https://doi.org/10.5402/2012/837270)
- [25] De Oliveira Gomes C, Drummond SN, Jham BC, Abdo EN, Mesquita RA. A survey of 460 supernumerary teeth in Brazilian children and adolescents. *Int J Paediatr Dent*. 2008;18:98-106.
DOI: [10.1111/j.1365-263X.2007.00862.x](https://doi.org/10.1111/j.1365-263X.2007.00862.x)