





CLINICAL STUDY

Assessment of the Nasal Shape after Orthognathic Maxillary Surgery

Farid Bourzgui¹ , Samir Diouny¹ , Idriss Tougui² , Ayoub El Omari³ ,
Zineb Serhier⁴ , Mohamed Bennani Othmani⁴ 

¹ Faculty of Dental Medicine, University Hassan II, Casablanca, Morocco

² Maxillofacial Surgeon, My Youssef Hospital, Casablanca Morocco

³ Private Practice, Casablanca, Morocco

⁴ Laboratory of medical informatics, University Hassan II, Faculty of Medicine & Pharmacy, Casablanca, Morocco

ABSTRACT

Background: Orthodontic and surgical modifications have been shown to have aesthetic effects on the shape or position of the nose. **Aim:** To evaluate nasal changes using cephalometric assessment after orthognathic surgery. The PIDAQ was cross-culturally adapted into Malay version by forward- and backward-translation processes, followed by psychometric validation.

Methods: A cross-sectional study was carried out involving 20 Moroccan orthognathic patients from January to March 2019. Their mean age was 22.40 (+/-6.98 years). The amplitude of the surgical movements of all patients was measured using measurements on profile telerradiographs and photos of faces taken before and after surgery. The statistical analysis of cephalometric data before and after surgery was performed using the Wilcoxon test. The significance level was $p \leq 0.05$.

Results: The results revealed a significant reduction in the angular values of SNA ($^{\circ}$) ($p < 0.001$), GoGn/SN ($^{\circ}$) ($p = 0.038$), Occ/Sn ($^{\circ}$) ($p = 0.007$) and AoBo (mm) ($p = 0.025$). No statistically significant differences were noted for specific cephalometric variables before and after surgery as for facial photographs. All the values of the specific measurements before and after were significant except Prn - SN.

Conclusion: The width of the base of the nasal wing and the displacement and the amount of rotation of the nasal tip increased considerably in most patients while the X-axis to Prn distance decreased.

KEYWORDS: Aesthetics, Orthodontics, Orthognathic surgery, Le Fort I osteotomy, Nose.

Correspondence: Pr Farid Bourzgui, Faculty of Dental Medicine, University Hassan II, Casablanca, Morocco.

Email: farid.bourzgui@etu.univh2c.ma

Copyright © 2021 Bourzgui F et al. This is an open access article distributed under the [Creative Commons Attribution 4.0 International](https://creativecommons.org/licenses/by/4.0/), which permits unrestricted use, distribution, and reproduction in any medium, provided the original work is properly cited.

Key Points:

On the basis of this study, it can be concluded that after orthognathic surgery, there was:

- An increase in the width of the base of nose wings.
- A decrease of the distance X-Prn axis.
- An increase in the value of the nasal tip displacement.
- An increase in the amount of rotation of the nasal tip in the most cases.

BACKGROUND

Dentofacial deformities primarily affect the maxillary and mandibular bone, distorting facial aesthetics and affecting masticatory function. Dentofacial deformities, in which the facial skeleton differs from the accepted normal, alter the maxillomandibular complex and facial appearance.

They often cause a range of impacts on physical function and facial aesthetics and negatively impact people's emotional and social well-being (1).

Patients who seek orthognathic surgery may have varying degrees of functional or aesthetic impairment. Depending on the nature and severity of the dentofacial deformity,

surgery can range from a simple mobilization of groups of teeth by segmental osteotomy to complex mobilization of the mandible and/or maxilla. Orthognathic surgery is indicated when traditional orthodontic treatment alone cannot effectively correct bone base discrepancies (2). Orthognathic surgery is an optional facial surgery procedure. Orthognathic surgery aims to correct facial differences and improve masticatory function and facial aesthetics (3). Le Fort, I osteotomy is a procedure performed by maxillofacial surgeons to correct a wide range of dentofacial deformities. It includes procedures performed in bone, cartilage, and soft tissues of the nose that can cause nasal shape and function changes, which are sometimes unpredictable (4).

Bimaxillary orthognathic surgery is now a well-established and commonly used treatment to correct dentofacial deformities. Several studies have reported the positive effects of orthognathic surgery on the psychological, social, and esthetic aspects of quality of life among patients after surgery (5). Taking into account the relationship between the maxillae and the nose it is necessary to determine the extent to which displacements in the three directions of space secondary to maxillary surgery can modify the shape and dimensions of the nose. Thus, this study aimed to evaluate the nasal shape by cephalometric study in patients undergoing orthognathic surgery.

METHODS

This cross-sectional study was conducted to compare cephalometric changes of the nose involving 20 Moroccan adult patients (17 Females and three males) with an age range of 22.40 years (SD: 6.98 years). All patients were treated by the same orthodontist and maxillofacial surgeon from January 2015 to December 2020 at the University Hospital in Casablanca-Morocco. The treatment plan included three types of surgery:

Upper jaw surgery

Bimaxillary surgery

Bimaxillary surgery associated with genioplasty

The clinical data collected from the medical records and subjected to the analysis included digital images of teleradiographies (performed by Panoramic & Ceph Genoray) before and after surgery (at least after six months) with the same magnification and photos of the beginning and end of treatment taken under the same conditions.

Patients with 1st arch syndrome, Marfan syndrome, and all forms of facial cleft, mandibular surgery, and genioplasty without upper jaw surgery and incomplete records were excluded from the study.

All patients underwent the same surgical protocol, and all patients had a nasal cinch suture. In the case of bimaxillary surgery, the maxilla was always repositioned first, followed by the mandible. Osteosynthetic fixation was provided in the maxilla, I-shaped on the right side, J-shaped on the left, and I-shaped on the mandible.

Measurements of the amplitude of the surgical movements on profile teleradiographs and photos of faces taken before and after surgery were recorded. The profile teleradiographs were taken with the same X-ray equipment, at two different times (before and after surgery), T1, pre-surgical (after orthodontics preparation or at the beginning of treatment), T2, post-surgery, at least

6 months after surgery, to determine and quantify the aesthetic repercussions on the nose. Then, a cephalometric analysis was performed; it consisted of two parts: the first part was skeletal and dental cephalometry (Table1). The second component was specific cephalometry (Table2). Figure 1 illustrates measurements of the specific cephalometric analysis. The front photos of the 20 patients at the beginning and after surgery were standardized using the "Image J software" for Windows PC, which allowed measurements of the width of the wing base of the nose (figure 2).

The data were processed by breaking down the quantitative variables into their mean and standard deviation and the qualitative variables into numbers and percentages. The statistical analysis of cephalometric data before and after surgery was performed using the Wilcoxon test. The significance level was set at $p \leq 0.05$. Approval for the study was granted by the Ethics Research Committee of Casablanca Dental School (Under the number 42/2020). Data were analyzed using the Statistical SPSS software, version 16.0, SPSS Inc; Chicago, IL, USA. All participants were informed about the different aspects of the study.

Table 1 : Classical cephalometric analysis.

Variables	Definitions
SNA (°)	Angle formed between the turcic saddle-Nasion point line and the Nasion-Point A line.
SNB (°)	Angle formed between the turcic saddle-Nasion point line and the Nasion-Point B line.
ANB (°)	The difference between SNA and SNB.
SND (°)	Angle formed between the turcic saddle-Nasion point line and the Nasion-Point D line.
GoGn/SN (°)	Angle formed by a tangent to the horizontal branch of the mandible between the gonion and gnathion point and the turcic saddle- Nasion point line.
Occ/SN (°)	Angle formed by the occlusal plane and the turcic saddle- Nasion point line.
I/NA (°)	Angle that the axis of the upper central incisor makes with the Nasion-Point A line.
I/NB (°)	Angle that the axis of the upper central incisor makes with the Nasion-Point B line.
I/i (°)	Angle formed by the intersection of the two incisal axes.
FMA (°)	Angle formed by the Frankfurt plane and the tangent to the lower edge of the mandible.
Facial convexity (°)	Angle formed by the glabella-sub-nasal line and the sub-nasal line - Cutaneous pogonion.
Changes of palatal plane (°)	Angle between the palatal plane (formed by the anterior and posterior nasal spine) and the Frankfurt plane.
Upper occlusal plane – FH (°)	The upper occlusal plane connects the incisal edges of the upper central incisors with a 0.5 mm occlusal point at the tip of the mesiobuccal cusp of the first permanent molar.
Lower facial height (mm)	Distance between the sub-nasal point and the gnathion.
Overjet (mm)	A horizontal overhang refers to the distance between the maxillary central incisors and the mandibular central incisors. It is measured in millimetres between the incisal tips.

AoBo (mm)	Distance between the orthogonal projection of Point A and Point B on the occlusal plane.
I/NA (mm)	Orthogonal projection on Nasion-Point A, of the point furthest from the crown of the upper central incisor. This is a millimetre value.
I/NB (mm)	Orthogonal projection on Nasion-Point B, of the point furthest from the crown of the upper central incisor. This is a millimetre value.
Pog/NB (mm)	Distance measured from the bone pogonion perpendicular to the Nasion-Point B line.
ANS-PNS (mm)	Distance between the anterior and posterior nasal spine to measure the total length in the sagittal section.

Table 2 : Specific cephalometric analysis

Variables	Definitions
N'-SN (mm)	Distance between the N' point (horizontal projection of the Nasion point on the skin tissue) and the sub-nasal point. It is used to measure the height of the nasal soft tissue.
Prn-SN (mm)	Distance between the Pronasal point and the sub-nasal point. It is used to measure the length of the nasal soft tissue in the sagittal section.
N-ANS (mm)	Distance between the Nasion point and the anterior nasal spine to measure the nasal height in the sagittal section.
Nasal tip height (mm)	Distance between the Pronasal point and the X axis. The X-axis is a horizontal line starting from the point N, rising 7° from the line SN.
Nasal tip displacement (mm)	Distance between the Pronasal point and the Y-axis. The Y-axis is a vertical line perpendicular to the horizontal line passing through the S-point.
Nasal tip rotation (°)	Angle between the SN line and the Nasion-Pronasal line.
Nasal tip width (cm)	The width was obtained by measuring the distance between the most lateral points of the nostrils.

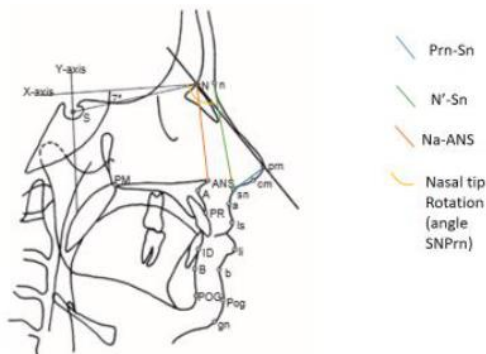


Figure 1 : Specific cephalometric analysis measurements.

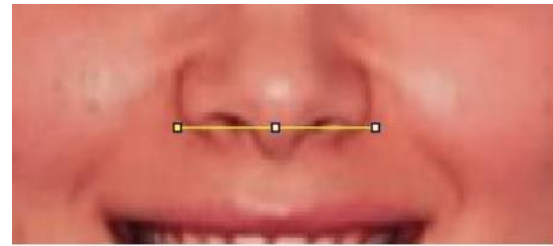


Figure 2 : Measuring the width of the wing base of the nose with the Image J software.

RESULTS

In the current study, the sample consisted of 20 patients (17 females and three males). The mean age was 22.40 years. All the patients had a chief esthetic complaint. The majority of participants (95%) were of a hyper-divergent facial type, and the nose-lip-chin relationship was stretched in 85% of the cases. With respect to the sagittal direction, 70% had a retrusive position of the middle stage about the base of the skull, and 60% had a projected part of the lower stage to the center stage. 70% of the patients had class III skeletal deformities, while 30% had skeletal class II deformities. 95% of patients benefited from bimaxillary surgery, 50% of which had genioplasty. Only 5% of the patients benefited from upper jaw surgery.

Results of the post-operative changes in skeletal and dental cephalometric values indicated the following significant variations:

An increase in SNA (°) was noted with a median of 4.13 (p<0,001).

A decrease in the GoGn/SN ratio (°) was noted with a median of -1.75 (p=0,038).

A decrease in the OCC/SN ratio (°) was noted with a median of -4.88 (p=0,007).

A decrease in the I/Na ratio (°) was noted with a median of -3.5 (p=0,040).

An increase in Overjet (mm) was noted with a median of 4.5 (p=0,018).

An increase in AoBo (mm) was noted with a median of 4.5 (p=0,025).

A decrease in the I/NB ratio (mm) was noted with a median of -0.88 (p=0,004).

An increase in the Pog/NB ratio (mm) was noted with a median of 1.13 (p=0,001).

No statistically significant difference was observed for specific measures before and after surgery (Table 3). An increase in the average nasal tip width (cm) was observed between before and after surgery (Table 4). All the values of the variables between before and after surgery were significant, except for the value of Prn - SN (mm) between before and after surgery which was not (Table 5).

Table 3 : Evolution of specific cephalometric variables after surgery.

Measures	Difference (After- before) Median	P
N'-Sn (mm) TP	0	0.845
Prn - Sn (mm) TP	-0.25	0.628
N - ANS (mm) TP	-0.75	0.658
Nasal tip height (mm) TP	-0.75	0.159
Nasal tip displacement (mm) TP	0.25	0.338
Nasal tip rotation (°) TP	4.5	0.108
Nasal tip width (cm) Photo	-0.08	0.872
	0.09	0.248
	0.10	0.178

Table 4: Mean of the variables of the specific cephalometry.

Variables	Mean
N'- SN (mm) after	48.3875
N'- SN (mm) before	48.4875
Prn - SN (mm) after	16.625
Prn - SN (mm) before	16.225
N - ANS (mm) after	44.250
N - ANS (mm) before	44.4000
Nasal tip height (mm) after	36.9375
Nasal tip height (mm) before	38.6000
Nasal tip displacement (mm) after	82.8250
Nasal tip displacement (mm) before	80.9000
Nasal tip rotation (°) after	118.7125
Nasal tip rotation (°) before	116.0750
Nasal tip width (cm) after	5.40416
Nasal tip width (cm) before	5.47384
Nasal tip width (cm) after	5.38680
Nasal tip width (cm) before	5.37185
Nasal tip width (cm) after	6.56947
Nasal tip width (cm) before	6.32495

Table 5 : Significance of specific cephalometric variables

Variables after & before	Degrees of significance.
N' - SN (mm)	.000
Prn - SN (mm)	.328
N - ANS (mm)	.000
Nasal tip height (mm)	.000
Nasal tip displacement (mm)	.000
Nasal tip rotation (°)	.044
Nasal tip width (cm)	.010
Nasal tip width (cm)	.001
Nasal tip width (cm)	.000

DISCUSSION

This study investigated the aesthetic changes (dimensional and positional) of the nose by cephalometric study in a sample of 20 patients undergoing jaw surgery. The results reported a significant decrease in the angular values of ANS (°) ($p < 0.001$), GoGn/SN (°) ($p = 0.038$), Occ/SN (°) ($p = 0.007$) and AoBo (mm) ($p = 0.025$). Regarding specific cephalometric variables, no statistically significant difference was observed (Table 3). After comparing the front photos, all the values of the variables between before and after was significant in the specific measurements except for Prn - SN after and before (Table 5).

As for the width of the base of the nose, an increase of +2.4452 mm was observed. These width values were significant. Van Loon B et al. 2015 (4) investigated the changes in the nasal region and upper lip after orthognathic surgery using combined cone-beam computed tomography (CBCT) and three-dimensional (3D) stereophotogrammetry datasets. Their sample consisted of 36 patients (12 men and 24 women) with a mean age of 26.9 years (range 17-55 years). Of these patients, 12 (five men and seven women) had a Le Fort I osteotomy while the others (7 men and 17 women) had bimaxillary surgery. The average inter-alar width between before and after surgery was 1.76 mm. The value of the difference in wing width was 1.81 mm. Van Loon B et al. 2015 reported that soft tissue measurements showed a statistically significant increase in inter-wing width ($P < 0.001$). The nose widened after surgery (4). Regression analysis of jaw mobilizations versus soft tissue changes showed a positive correlation between jaw translation and jaw mobilization, indicating an increase in nose wing width. Anterior

translation and clockwise rotation of the maxilla were significantly associated with an increase in lip volume. Anterior translation of the jaw did not significantly affect the importance of the nose (4).

Dantas WR et al. 2014 (6) reported an increased nose width independent of the amount of jaw protrusion with either anterior or posterior impaction in most cases. They recorded an enlargement of the inter-alar width, both before surgery (mean 35.50) and after surgery (mean 38.25). This width was determined by caliper measurement of the most lateral point of the nostrils. They concluded that maxillary advancement and superior repositioning procedures tended to lead to elevation and improvement of the nasal tip and widening of the nasal base.

According to Worasakwutiphong S et al. 2015 (7), nasal modifications in these cases showed a slight increase in wing width and decreased columellar inclination. Interestingly, only 5% of the subjects presented complaints about these nasal variations. The enlargement of the nose in the two dissatisfied individuals was not extreme. The low rate of dissatisfaction may be due to the low intensity of nasal change combined with a significant enhancement of facial aesthetics and dental functioning.

Park S.B et al. 2012 (8) conducted a study involving 15 males and 15 females; the mean age was 22.4 years +/- 2.9 years; age range, 19 to 30 years with previously diagnosed class III skeletal malformations. None of the patients had craniofacial syndromes, cleft lip, and palate, or severe facial asymmetry. The same surgeon performed the same operative procedure: the Le Fort I osteotomy was shifted anteriorly and superiorly, whereas, on the mandible, a bilateral sagittal split osteotomy was performed. Postoperative assessment of the nasal modification showed that the width of the wing base increased on average by 2.45 +/- 1.52 mm ($p < 0.05$). In their study, Chung C et al. 2008 (9) claimed that, following surgery, the width of the wing and the base of the wing were significantly augmented ($P < 0.001$), while the projection of the tip of the nose was attenuated ($P < 0.001$). The morphology of the nostrils also revealed an enlargement ($P < 0.001$). Women with narrow preoperative wing widths tended to have more nasal enlargement than wider wing widths ($P < 0.05$).

Regarding the depth of the nose (Prn-Sn), Honrado CP et al. 2006 (10), who used the exact measurement as in the present study, did not report any change in the depth of the nose either. Magnusson A et al. 2013 (11), by assessing the length of the nasal soft tissue, the average increase was estimated to be +3.09 mm. In our study, the value of Prn - SN (mm) before surgery was 16.225 mm and after surgery 6.625 mm, with an increase of 0.4mm, which was non-significant ($p = 0.328$).

In the present investigation, nasal height was set to measure the gap between the Pronasal point and the X-axis. The X-axis is a horizontal line from the N-point, rising 7° from the SN-line. Its average value in (mm) after surgery was 36.9375. Its average value in (mm) before surgery was 38.6000. We noticed that this height decreased after surgery. The value of the decrease was 1.6625mm. These results were in line with those of Dantas WR et al. 2014 (6), who noted a reduction in the measurement of the distance of the X-Prn axis between the preoperative and postoperative periods. We also measured

the distance N'-SN between before and after surgery. The mean value of N'-SN (mm) before surgery was 48.4875. The mean value of N'-SN (mm) after surgery was 48.3875. We observed a decrease of -0.1mm. Worasakwutiphong S et al. 2015 (7) considered N'-SN as the nasal height. After the surgical procedure, no significant postoperative variations were detected about the size and length of the nose. Park SB et al. 2012 (8) considered N-Prn as the nasal height (N: orthogonal projection of the nasion on the soft tissues. Prn: pro nasal). This nasal height, which was related to vertical position variations, declined by 2.38 mm (from a mean of 48.27 preoperatively to 45.89 postoperatively). Unlike our study, which used 2-dimensional analysis, Coban et al., 2020 (12) evaluated the changes in the nose in three dimensions after Le Fort I osteotomy in patients with skeletal Class III malocclusion using Stereophotogrammetry. In this study, the researchers found out that nasal soft tissues were highly affected by the vertical movement of the maxilla; however, the smooth tissue responses were individual-dependent.

For nasal tip displacement (top of the nose), we measured the distance between the Pronasal point and the Y-axis. The Y-axis is a perpendicular line to the horizontal line passing through point S. The results of this study agreed with those of Dantas WR et al. 2014 (6). Comparison of pre-and postoperative measurements of the Y-Prn axis showed an increase in this distance between the two assessments, indicating that a forward displacement of the nasal tip was noted in 80% of cases.

Concerning the rotation of the nasal tip, the angle between the SN line and the Nasion-Pronasal line was measured. According to Dantas WR et al. 2014 (6), the comparison of the pre-and post-operative SnPrn angle measurements showed an upward rotation of the nasal tip in 80% of cases, downward rotation in 10% of cases and no rotation of the nasal tip in 10% of patients. These results were somewhat similar to ours; the value of this increase was +2,6375°. After the intervention, the value of the nasal tip rotation

increased in most cases, and the value of the nasal tip rotation was significantly higher.

Soft tissue changes after orthognathic surgery were not predictable, particularly in the midface. Software for predicting smooth tissue changes (13) is currently not powerful and should be used with caution (14). The use of CBCT DICOM data and 3D stereophotogrammetry has shown interest in the 3D analysis of changes in the maxillary skeleton and overlying soft tissue. Data could be acquired and likened to study the influence of jaw movement on the soft tissues of the nose and upper lip. The ability to predict nasal soft tissue changes after maxillary and mandibular surgery has been studied anthropometrically in two dimensions (2D) using plaster casts, with photographs, by profile telerradiography (15, 16) and in three dimensions (3D) (10,17). The morphological change of the nose according to the maxillary advancement and the upward movement was

CONCLUSION

The combination of orthodontics and orthognathic surgery is necessary to correct any abnormalities in the position or size of the jaw. Both surgical and orthodontic treatments can have an impact on the surrounding tissues, including the nose. Based on the present study, we can conclude that after orthognathic, both the width of the base of the nasal wing and the displacement and the amount of rotation of the nasal tip indicated an upward trend in most patients. At the same time, there was a downward trend in the X-axis to Prn distance. During an orthodontic-surgical treatment, the face changes as a whole. Even if the nose varies little in its dimensions, the patient may perceive it differently, depending on the general context. It is, therefore, necessary to inform patients about the expected results. The smooth running of the orthodontic-surgical protocols and their consequences, especially aesthetic results, are based on specialized knowledge and close and effective collaboration of orthodontists and oral surgeons.

AUTHORS' CONTRIBUTIONS

All the authors have actively participated in the redaction, the revision of the manuscript, and provided approval for this final revised version.

ACKNOWLEDGMENTS

None.

REFERENCES

- [1] Feragen KB, Stock NM. Psychological adjustment to craniofacial conditions (excluding oral clefts): A review of the literature. *Psychol Health*. 2017 Mar;32(3):253-288. DOI: [10.1080/08870446.2016.1247838](https://doi.org/10.1080/08870446.2016.1247838)
- [2] Khamashta-Ledezma L, Naini FB. Systematic review of changes in maxillary incisor exposure and upper lip position with Le Fort I type osteotomies with or without cinch sutures and/or VY closures. *Int J Oral Maxillofac Surg*. 2014 Jan;43(1):46-61. DOI: [10.1016/j.ijom.2013.08.005](https://doi.org/10.1016/j.ijom.2013.08.005)
- [3] Silva MAS, Médiçi Filho E, Castilho JCM, Gil CTLA. Assessment of divine proportion in the cranial structure of individuals with Angle Class II malocclusion on lateral cephalograms. *Dental Press J Orthod*. 2012 Jun;17(3):88-97. DOI: [10.1590/S2176-94512012000300018](https://doi.org/10.1590/S2176-94512012000300018)
- [4] van Loon B, van Heerbeek N, Bierenbroodspot F, Verhamme L, Xi T, de Koning MJ, et al. Three-dimensional changes in nose and upper lip volume after orthognathic surgery. *Int J Oral Maxillofac Surg*. 2015 Jan;44(1):83-9. DOI: [10.1016/j.ijom.2014.08.001](https://doi.org/10.1016/j.ijom.2014.08.001)
- [5] Al-Asfour A, Waheedi M, Koshy S. Survey of patient experiences of orthognathic surgery: health-related quality of life and satisfaction. *Int J Oral Maxillofac Surg*. 2018 Jun; 47(6): 726-731. Doi: [10.1016/j.ijom.2017.12.010](https://doi.org/10.1016/j.ijom.2017.12.010)
- [6] Dantas WR, Silveira MM, Vasconcelos BC, Porto GG. Evaluation of the nasal shape after orthognathic surgery. *Braz J Otorhinolaryngol*. 2015 Jan-Feb;81(1):19-23. DOI: [10.1016/j.bjorl.2014.08.005](https://doi.org/10.1016/j.bjorl.2014.08.005)
- [7] Worasakwutiphong S, Chuang YF, Chang HW, Lin HH, Lin PJ, Lo LJ. Nasal changes after orthognathic surgery for patients with prognathism and Class III malocclusion: analysis using three-dimensional photogrammetry. *J Formos Med Assoc*. 2015 Feb; 114(2):112-23. DOI: [10.1016/j.jfma.2014.10.003](https://doi.org/10.1016/j.jfma.2014.10.003)
- [8] Park SB, Yoon JK, Kim YI, Hwang DS, Cho BH, Son WS. The evaluation of the nasal morphologic changes after bimaxillary surgery in skeletal class III malocclusion by using the superimposition of cone-beam computed tomography (CBCT) volumes. *J Craniomaxillofac Surg*. 2012 Jun;40(4):e87-92. DOI: [10.1016/j.jcms.2011.05.008](https://doi.org/10.1016/j.jcms.2011.05.008)
- [9] Chung C, Lee Y, Park KH, Park SH, Park YC, Kim KH. Nasal changes after surgical correction of skeletal Class III malocclusion in Koreans. *Angle Orthod*. 2008 May;78(3):427-32. DOI: [10.2319/041207-186.1](https://doi.org/10.2319/041207-186.1)

COMPETING INTERESTS

The authors declare no competing interests with this study.

FUNDING SOURCES

None.

- [10] Honrado CP, Lee S, Bloomquist DS, Larrabee WF Jr. Quantitative assessment of nasal changes after maxillomandibular surgery using a 3-dimensional digital imaging system. *Arch Facial Plast Surg*. Jan-Feb 2006;8(1):26-35.
DOI: [10.1001/archfaci.8.1.26](https://doi.org/10.1001/archfaci.8.1.26)
- [11] Magnusson A, Bjerklind K, Kim H, Nilsson P, Marcusson A. Three-dimensional computed tomographic analysis of changes to the external features of the nose after surgically assisted rapid maxillary expansion and orthodontic treatment: a prospective longitudinal study. *Am J Orthod Dentofacial Orthop*. 2013 Sep; 144(3):404-13.
DOI: [10.1016/j.ajodo.2013.04.013](https://doi.org/10.1016/j.ajodo.2013.04.013)
- [12] Coban G, Yavuz I, Karadas B, Demirbas AE. Three-dimensional assessment of nasal changes after maxillary advancement with impaction using stereophotogrammetry. *Korean J Orthod*. 2020 Jul 25;50(4):249-257.
DOI: [10.4041/kjod.2020.50.4.249](https://doi.org/10.4041/kjod.2020.50.4.249)
- [13] Thomas PM. Three-Dimensional Soft Tissue Simulation in Orthognathic Surgery. *Atlas Oral Maxillofac Surg Clin North Am*. 2020 Sep; 28(2):73-82.
DOI: [10.1016/j.cxom.2020.05.003](https://doi.org/10.1016/j.cxom.2020.05.003)
- [14] Knoop PGM, Borghi A, Ruggiero F, Badiali G, Bianchi A, Marchetti C, Rodriguez-Florez N, Et Al. A novel soft tissue prediction methodology for orthognathic surgery based on probabilistic finite element modelling. *PLoS One*. 2018 May 9; 13(5):e0197209.
DOI: [10.1371/journal.pone.0197209](https://doi.org/10.1371/journal.pone.0197209)
- [15] Betts NJ, Vig KW, Vig P, Spalding P, Fonseca RJ. Changes in the nasal and labial soft tissues after surgical repositioning of the maxilla. *Int J Adult Orthodon Orthognath Surg*. 1993;8(1):7-23.
- [16] Soft and hard tissue changes after bimaxillary surgery in Turkish female Class III patients. *J Craniomaxillofac Surg*. 2009 Jan;37(1):8-17.
DOI: [10.1016/j.jcms.2008.07.004](https://doi.org/10.1016/j.jcms.2008.07.004)
- [17] Maal TJ, de Koning MJ, Plooi JM, Verhamme LM, Rangel FA, Bergé SJ, et al. One year postoperative hard and soft tissue volumetric changes after a BSSO mandibular advancement. *Int J Oral Maxillofac Surg*. 2012 Sep;41(9):1137-45.
DOI: [10.1016/j.ijom.2012.04.004](https://doi.org/10.1016/j.ijom.2012.04.004)