

## **CASE REPORT**

# **PRIMARY BREAST LEIOMYOSARCOMA IN MALE A CASE REPORT**

Pr Adil Aarsalane <sup>1</sup> , MD ; Pr Abdelfetah Zidane <sup>1</sup>, MD ; Pr Smail Saadi <sup>2</sup>, MD ; Pr Yassine Msougar <sup>3</sup>, MD

<sup>1</sup> Department of Thoracic surgery, Military Teaching Hospital Ibn Sina, University Cadi Ayaad, Morocco.

<sup>2</sup> Department of Medical Oncology, Military Teaching Hospital Ibn Sina, University Cadi Ayaad, Morocco

<sup>3</sup> Department of Thoracic surgery, Teaching Hospital Mohammed VI, University Cadi Ayaad, Morocco.

### **ABSTRACT**

Primary Sarcomas of the breast account for less than 1% of breast tumors. Leiomyosarcomas are less common. Only 51 cases have been reported in the literature, which only 4 cases in men. We present a new case of male breast leiomyosarcoma and discuss management and therapy of these unusual neoplasms. The confirmation of diagnosis was obtained by immunohistochemical study of surgical biopsy. The patient underwent a radical mastectomy and axillary lymphadenectomy. Adjuvant radiotherapy was indicated. Two years after surgery the patient is still in life without recurrence.

**KEY WORDS:** Breast – Sarcoma- Stromal tumors- Leimiyosarcoma.

### **Corresponding author:**

Dr Aarsalane Adil, Department of thoracic surgery, Military Teaching Hospital Ibn Sina, University Cadi Ayaad, Marrakech  
Phone number: +212639174901 ; Email : [arsalaneadil@gmail.com](mailto:arsalaneadil@gmail.com)

### **Copyright © 2017 Dr Adil Aarsalane et al.**

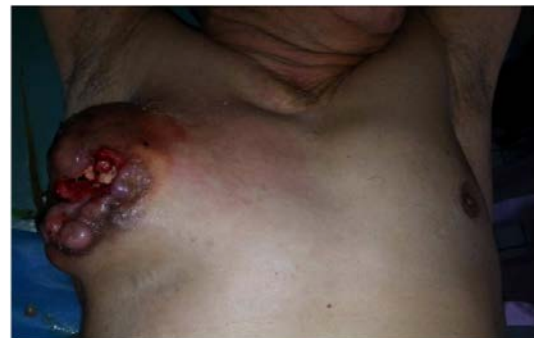This is an open access article distributed under the [Creative Commons Attribution 4.0 International](https://creativecommons.org/licenses/by/4.0/), which permits unrestricted use, distribution, and reproduction in any medium, provided the original work is properly cited.

### **INTRODUCTION**

Primary sarcomas of the breast account for less than 1% of all primary breast tumours. [1, 2] The subtype Leiomyosarcoma (LMS) is less common. [3] Its current prevalence is 0.0006%. [4] This tumor arise from the mesenchymal tissue of breast and occurs usually in postmenopausal women. [5]. It occurrence in man is even rarer. We present a new case of male breast leiomyosarcoma and discuss management and therapy of these unusual neoplasms.

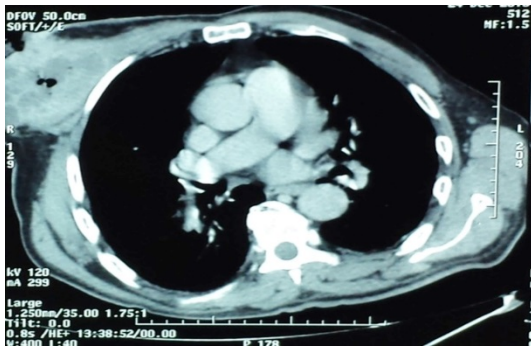
### **CASE REPORT**

A 68-year-old man, without history of malignancy or prior radiation therapy on chest wall, was admitted for the management of painless tumefaction of the right breast growing gradually since 1 year, with inflammatory signs and invasion of adjacent skin. These symptoms were associated to anorexia and weight loss of 5 kilograms in 3 months. On Physical examination, we found a central ulcerated mass of the right breast (fig 1), attached to the deep plan of the chest wall with inflammatory signs and axillary lymphadenopathy. Computed tomography of the chest (fig 2) showed a tumor of 8x9 cm in diameter involving major pectoralis muscle without ribs involvement or pulmonary metastasis.



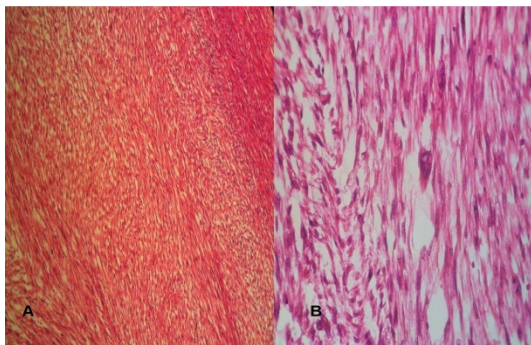
**Figure 1:** Ulcerated right breast mass

Surgical biopsy was performed, which histopathologic analysis revealed a proliferation of fusiform cells with atypical mitosis (9 to 10 by field) (fig 3). Immunohistochemical staining (fig 4 and 5) was positive intense and diffuse to Ki 67, SMA (smooth muscle actin), H'Caldesmon, negative to PS100 and to cytokeratin (AE1/AE3). A diagnosis of leiomyosarcoma was established. Initial workup including CT scan of whole body and bone scan was normal.

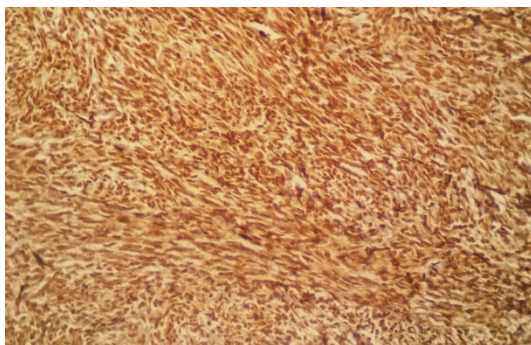


**Figure 2:** CT showing large right breast mass void of chest wall extension and no evidence of lung metastases.

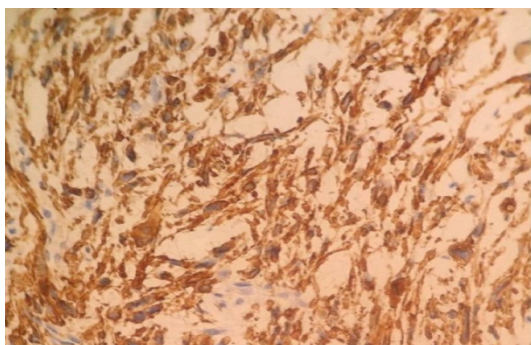
The patient underwent a radical mastectomy with resection of pectoralis muscle, axillary dissection, and immediate reconstruction with latissimus dorsi flap. Final histopathologic analysis of surgical specimen (fig 6) showed a necrotic tumor measuring 11x8x10 cm in diameter with free surgical margins (3 mm to the deep plan and 3cm to lateral margins) and confirmed the diagnosis of leiomyosarcoma grade II of FNCLCC.



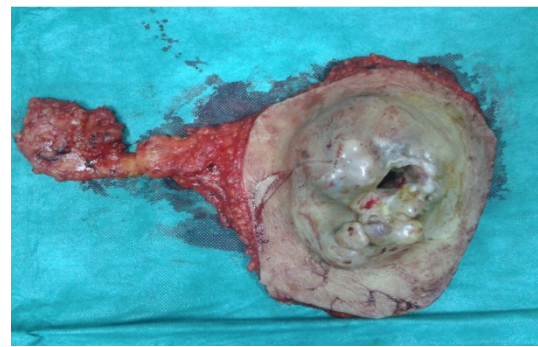
**Figure 3:** H&E staining at high-power magnification highlights spindle cells with encapsulated nuclei. A: x40 B: x100



**Figure 4:** Immunohistochemical analysis showed staining for smooth-muscle actin (x250)



**Figure 5:** Immunohistochemical analysis showed staining for H-caldesmon (x40)



**Figure 6:** Piece of mastectomy with cleaning lymph node

All the 21 lymph nodes sampled were not involved. The patient received an adjuvant radiation therapy to the tumor bed and adjacent chest wall, at the dose of 50 Gy in 25 fractions of 2 Gy, five fractions per week, using 6 MV photons of Linac. After a close follow up of 9 months we have not detected any local recurrence or distant metastasis.

## DISCUSSION

Breast sarcomas are rare and represent less than 1% of breast tumors [1, 2]. Primary breast leiomyosarcoma are even rarer. In the scanned literature 51 cases have been reported prior to this observation. [3, 5-10] They were 47 women and only 4 men with median age of 56 years (24-83 years). Their occurrence in men suggests the absence of endocrine factors in the genesis of these tumors [1, 11]. They develop from smooth muscles of areola or blood vessels [12]. Clinically we always found a painless mass growing progressively without invasion of deep structures of the chest wall [2]. In our case the major pectoralis muscle was massively invaded. Diagnosis is based on electron microscopy, histopathologic and immunohistochemical analysis of surgical biopsy performed before any treatment. These tumors usually express Smooth muscle actin, Desmine, and Vimentine and are negative staining for S100, cytokeratins, and epithelial markers [1, 2]. Mitotic activity of these tumors varies from 0 to 24 mitosis/10 high power field (HPF) with a mean of 11 mitosis/ HPF. [13] Surgery is the mainstay of treatment and the only guaranty of cure. The standard surgical procedure is radical mastectomy with surgical margins of at least 3 cm [12]. The risk of regional lymphatic extension is low and analysis of the case reports in the literature shows that lymphadenopathy usually corresponds to hyperplasia rather than a tumor, then axillary dissection is not mandatory [3, 5, 9, 12]. In our case axillary dissection has been done because physical exam found axillary macroscopic lymphadenopathy. These tumors likely spread by haematogenous way to lung, bone, liver, and central nervous system [14-16]. There is no consensus about adjuvant treatment by chemotherapy or radiotherapy, and the benefit of these additional treatments seems uncertain. [1-8] Radiation therapy ameliorated the local control in 3 cases previously reported in the literature. [17-19] In our case the deep surgical margin was insufficient, then postoperative radiotherapy was indicated to reduce risk of local recurrence. Pazopanib is a new treatment option for patients with metastatic non-adipocytic soft-tissue sarcoma after previous chemotherapy. The PALETTE study enrolled 369 patients, assigned to receive pazopanib (n=246) or placebo (n=123). Median progression-free survival was 4.6 months (95% CI 3.7-4.8) for pazopanib compared

with 1.6 months (0.9-1.8) for placebo (hazard ratio [HR] 0.31, 95% CI 0.24-0.40;  $p < 0.0001$ ). [20] The combination of hyperthermia and pazopanib may have had a strong synergistic effect on the chest wall mass of the primary breast leiomyosarcoma. [8]

## CONCLUSION

Primary leiomyosarcoma of the breast is a rare tumour, even rarer in man. It can be a diagnostic challenge to clinicians as it has no specific clinical or radiological features. The final diagnosis is obtained by histopathological and immunohistochemical study. These tumors must be excised with a negative margin in

## AUTHORS' CONTRIBUTIONS

The participation of each author corresponds to the criteria of authorship and contributorship emphasized in the [Recommendations for the Conduct, Reporting, Editing, and Publication of Scholarly work in Medical Journals](#) of the [International Committee of Medical Journal Editors](#). Indeed, all the authors have actively participated in the redaction, the revision of the manuscript and provided approval for this final revised version.

## REFERENCES

- [1] Markaki S, Sortiropoulou M, Hanioti C, Lazaris D. Leiomyosarcoma of the breast: A clinicopathologic and immunohistochemical study. *Eur J Obstet Gynecol Reprod Biol* 106 (2003): 233-236
- [2] Munitiz V, Riosa A, Canovasa J, Ferrib B, Solab J, Canovasa P, Illanaa J, Parrilla P. Primitive leiomyosarcoma of the breast: case report and review of the literature. *The Breast* (2004) 13, 72–76
- [3] Agrawal P, Garg N, Pandey B. Primary leiomyosarcoma of breast: A rare case-report. *Cancer Treatment Communications* 6 (2016) 24–26.
- [4] Adem C, Reynolds C, Ingle J.N, Nascimento A.G. Primary breast sarcoma: clinic-pathologic series from the Mayo Clinic and review of the literature. *Br. J. Cancer* 91 (2004) 237–241.
- [5] Rane SU, Batra C, Saikia UN. Primary Leiomyosarcoma of Breast in an Adolescent Girl: A Case Report and Review of the Literature. *Hindawi Publishing Corporation Case Reports in Pathology Volume 2012*
- [6] Fujita N, Kimura R, Yamamura J, Akazawa K, Kasugai T, Tsukamoto F. Leiomyosarcoma of the breast: A case report and review of the literature about therapeutic management. *The Breast* 20 (2011) 389-393
- [7] Amaadour L, Benbrahim Z, Moumna K, Boudahna L, Amarti A, Arifi S, N. Mellas N, El Mesbahi O. Primary Breast Leiomyosarcoma. *Case Reports in Oncological Medicine Volume 2013*
- [8] Lee SY, Lee NR. Positive response of a primary leiomyosarcoma of the breast following salvage hyperthermia and pazopanib. *The Korean Journal of Internal Medicine.* 2016 Apr 15
- [9] Masannat Y, Sumrien H, Sharaiha Y. Primary Leiomyosarcoma of the Male Breast: A Case Report. *Case Reports in Medicine Volume 2010*
- [10] Kim BR, Lee JH, Cho E, Kim DC, Park YM, Ha DH, Choi S. Primary Breast Leiomyosarcoma located in the Premammary zone: A case Report. *Journal of Clinical Imaging* (2015)
- [11] Hussien M, Sivananthan S, Anderson N, Shiels A, Tracey N, Odling-Smee GW. Primary leiomyosarcoma of the breast: diagnosis, management and outcome. A report of a new case and review of literature. *The Breast* (2001) 10, 530-534
- [12] Chen KT, Kuo TT, Hoffmann KD. Leiomyosarcoma of the breast: a case of long survival and late hepatic metastasis. *Cancer* 1981; 1(47): 1883-1886.
- [13] Stafyla VK, Gauvin JM, Farley DR. A 53-year-old woman with a leiomyosarcoma of the breast. *Curr Surg* 2004; 61: 572-575.
- [14] Nielsen BB. Leiomyosarcoma of the breast with late dissemination. *Virchows Arch Pathol Anat* 1984; 403: 241–245.
- [15] Parham DM, Robertson AJ, Hussein KA. Leiomyosarcoma of the breast: cytological and histological features, with a review of the literature. *Cytopathology* 1992; 3: 245–252.
- [16] Wei CH, Wan CY, Chen A. Epithelioid leiomyosarcoma of the breast: report of a case. *J Formos Med Assoc* 1993; 92(4):379–381.
- [17] Jayaram G, Jayalakshmi P, Yip CH. Leiomyosarcoma of the breast: report of a case with fine needle aspiration cytologic, histologic and immunohistochemical features. *Acta Cytol* 2005; 49:656-660.
- [18] Vu LT, Luce J, Knudson MM. Image of the month: leiomyosarcoma of the breast. *Arch Surg* 2006 Dec;141:1263-1264.
- [19] Bassett P, Shaban J, Fulger I. Twenty-year-old female with leiomyosarcoma of the breast. *J Surg Case Rep.* 2014; 1
- [20] Van der Graaf WT, Blay JY, Chawla SP. Pazopanib for metastatic soft-tissue sarcoma (PALETTE): a randomised, double-blind, placebo-controlled phase 3 trial. *Lancet* 2012; 379:1879-1886.

The prognosis of primary breast leiomyosarcoma seems to be better than other breast sarcomas, but armed and prolonged follow up is mandatory to early detect local recurrence or distant metastasis. [1]

order to obtain good results. The benefits of chemotherapy, radiotherapy, and hormonal therapy are still controversial. Radiotherapy may be indicated if the tumour size is large or if the resection is incomplete. Several studies need to be done to determine the prognostic factors.

## PATIENT CONSENT

Written informed consent was obtained from the patient for publication of this case report.

## COMPETING INTERESTS

The authors declare no competing interests.